











## GUIDELINES

# Consensus statement on the diagnosis and treatment of sclerosing diseases of the skin, Part 2: Scleromyxoedema and scleroedema

Robert Knobler<sup>1</sup>  | Marija Geroldinger-Simić<sup>2,3</sup> | Alexander Kreuter<sup>4</sup> |  
 Nicolas Hunzelmann<sup>5</sup> | Pia Moinzadeh<sup>5</sup>  | Franco Rongioletti<sup>6</sup>  |  
 Christopher Denton<sup>7</sup>  | Luc Mouthon<sup>8,9</sup> | Maurizio Cutolo<sup>10</sup> | Vanessa Smith<sup>11,12,13</sup> |  
 Armando Gabrielli<sup>14</sup> | Martine Bagot<sup>15</sup>  | Anne B. Olesen<sup>16</sup> | Ivan Foeldvari<sup>17</sup> |  
 Ahmad Jalili<sup>18</sup>  | Veli Matti Kähäri<sup>19</sup> | Sarolta Kárpáti<sup>20</sup> | Kristian Kofoed<sup>21</sup> |  
 Malgorzata Olszewska<sup>22</sup> | Jaana Panelius<sup>23</sup> | Pietro Quaglini<sup>24</sup>  | Julien Seneschal<sup>25</sup>  |  
 Michael Sticherling<sup>26</sup> | Cord Sunderkötter<sup>27</sup> | Adrian Tanew<sup>28</sup>  | Peter Wolf<sup>29</sup> |  
 Margitta Worm<sup>30</sup> | Anna Skrok<sup>22</sup> | Lidia Rudnicka<sup>22</sup>  | Thomas Krieg<sup>31</sup>

### Correspondence

Robert Knobler, Department of Dermatology,  
 Medical University of Vienna, Vienna,  
 Austria.

Email: [robert.knobler@meduniwien.ac.at](mailto:robert.knobler@meduniwien.ac.at)

### Funding information

Mallinckrodt Pharmaceuticals

### Abstract

The term ‘sclerosing diseases of the skin’ comprises specific dermatological entities, which have fibrotic changes of the skin in common. These diseases mostly manifest in different clinical subtypes according to cutaneous and extracutaneous involvement and can sometimes be difficult to distinguish from each other. The present consensus provides an update to the 2017 European Dermatology Forum Guidelines, focusing on characteristic clinical and histopathological features, diagnostic scores and the serum autoantibodies most useful for differential diagnosis. In addition, updated strategies for the first- and advanced-line therapy of sclerosing skin diseases are addressed in detail. Part 2 of this consensus provides clinicians with an overview of the diagnosis and treatment of scleromyxoedema and scleroedema (of Buschke).

## SCLEROMYXOEDEMA

### Introduction

Scleromyxoedema, also known as diffuse/generalized and sclerodermoid lichen myxoedematosus or Arndt-Gottron disease, is a primary cutaneous mucinosis characterized by a generalized, papular and sclerodermoid, cutaneous eruption that usually occurs in association with monoclonal gammopathy.<sup>1</sup> Affected patients develop numerous waxy, firm papules and plaques that demonstrate mucin deposition,

increased fibroblast proliferation and fibrosis on histological grounds. Systemic manifestations may involve the cardiovascular, gastrointestinal, pulmonary, musculoskeletal, renal or nervous systems and may lead to significant morbidity and mortality.

Scleromyxoedema should be distinguished from localized lichen myxoedematosus, a form of lichen myxoedematosus that presents with waxy, firm papules and plaques involving limited areas. Unlike scleromyxoedema, sclerotic features, systemic involvement and monoclonal gammopathy are absent in localized lichen myxoedematosus. Systemic sclerosis

Marija Geroldinger-Simić, Alexander Kreuter, Nicolas Hunzelmann, Pia Moinzadeh, Franco Rongioletti, and Christopher Denton are contributed equally to this work.

For Affiliation refer page on 14

This is an open access article under the terms of the [Creative Commons Attribution-NonCommercial](https://creativecommons.org/licenses/by-nc/4.0/) License, which permits use, distribution and reproduction in any medium, provided the original work is properly cited and is not used for commercial purposes.

© 2024 The Authors. *Journal of the European Academy of Dermatology and Venereology* published by John Wiley & Sons Ltd on behalf of European Academy of Dermatology and Venereology.

and scleroedema are additional disorders that present with sclerodermoid features but are unrelated to scleromyxoedema. Scleromyxoedema is also distinct from generalized myxoedema of thyroid disease.

## Epidemiology

Scleromyxoedema is a rare disease that usually affects middle-aged adults between the ages of 30 and 80 years, with no race or sex predominance.<sup>1</sup> In a multicentre, retrospective study of 30 patients with scleromyxoedema, the mean age of affected patients was 59 years.<sup>1</sup> This illness is extremely rare or almost absent in infants and young children.

## Pathogenesis

The pathogenesis of scleromyxoedema is unknown. The significance of the associated monoclonal gammopathy and the underlying plasma cell clone is debated. The main hypothesis is that circulating cytokines, such as interleukin (IL)-1, tumour necrosis factor (TNF)-alpha and transforming growth factor (TGF)-beta, known to stimulate glycosaminoglycan synthesis and fibroblast proliferation in the skin, may play a role.<sup>2-4</sup>

A promoting role of TGF-beta has also been identified in case series by analysis of RNA in involved skin tissue.<sup>5,6</sup> New insights were added by a study in which abnormally high secretion of IL-4, a profibrotic cytokine, was found in serum from scleromyxoedema patients, suggesting a chronic Th2-skewed T cell response against an unknown target antigen.<sup>7</sup> The same study also found that both CD4+ and CD8+ T cells from patients with scleromyxoedema present a profound deficiency (even after stimulation) of the production of interferon-gamma and IL-17 compared to healthy donor control cells. The role of interferon-gamma in scleromyxoedema could be related to the lack of its inhibitory effect on both proliferation and extracellular matrix production by fibroblasts.

Clinical remission of scleromyxoedema following autologous stem cell transplantation suggests that the bone marrow may be a source of these circulating factors.<sup>2,8</sup>

Many authors have also suggested that paraproteins themselves may be pathogenic, acting as autoantibodies that stimulate fibroblasts to proliferate and overproduce mucin. However, there are data conflicting with this theory. Although serum isolated from patients with scleromyxoedema has enhanced fibroblast proliferation in some *in vitro* studies,<sup>8,9</sup> one of these studies also found that purified immunoglobulin from the serum did not stimulate fibroblast growth.<sup>8</sup> In addition, a study in which serum from a patient with scleromyxoedema was found to increase production of hyaluronic acid (a component of mucin) and prostaglandin E by fibroblast cultures did not find a stimulatory effect of the serum on fibroblast proliferation.<sup>10</sup> Moreover, paraprotein

levels usually do not correlate with the severity of disease, disease progression or the response to treatment.<sup>1</sup> Only on an anecdotal basis, has the complete resolution of skin lesions coincided with the normalization of the bone marrow and the disappearance of the paraprotein.<sup>11</sup>

Additional theories on the pathogenesis of scleromyxoedema have been proposed. It has been suggested that an intrinsic abnormality of scleromyxoedema fibroblasts may result in increased glycosaminoglycan synthesis.<sup>12</sup> In addition, case reports documenting the development of scleromyxoedema following a cutaneous, granulomatous reaction after intradermal hyaluronic gel injections<sup>13</sup> or after breast silicone implantation<sup>1</sup> may suggest a type of autoimmune syndrome induced by adjuvants.

## Clinical findings

The clinical manifestations of scleromyxoedema include both cutaneous and extracutaneous features.

### Cutaneous manifestations

The characteristic skin finding in scleromyxoedema is a widespread eruption of 2-3 mm, firm, waxy, closely spaced, dome-shaped or flat-topped papules involving the hands, forearms, head, neck, upper trunk and thighs.<sup>2,3</sup> Papules are often arranged in a strikingly linear array, and the surrounding skin is shiny and indurate (sclerodermoid) in appearance. Rarely, nontender subcutaneous nodules are present. The glabella is typically involved with deep, longitudinal furrows that produce the characteristic leonine face. Deep furrowing also is typically evident on the trunk or limbs associated with redundant skin folds (known as "Shar-Pei sign"). Erythema, oedema and a brownish discoloration may be seen in the involved areas; pruritus is not uncommon.

Eyebrow, axillary and pubic hair may be sparse in patients with scleromyxoedema. The mucous membranes are spared. As the condition progresses, erythematous and infiltrated plaques may appear with skin stiffening, sclerodactyly and decreased motility of the mouth and joints. On the proximal interphalangeal joints, a central depression surrounded by an elevated rim (due to skin thickening) can be present and is referred to as the 'doughnut sign'. Unlike scleroderma, telangiectasias and calcinosis are absent. Although rare, the Raynaud phenomenon occurs, and when associated with sclerodactyly and decreased motility can pose a mimic of SSc, demanding careful further diagnostic measures.

### Extracutaneous manifestations

Patients with scleromyxoedema can have a number of internal implications, including neurological, rheumatological, cardiovascular, gastrointestinal, pulmonary and renal manifestations. In a multicentre, retrospective study

of 30 patients with scleromyxoedema, the most common extracutaneous manifestations were neurological abnormalities (30%), rheumatological abnormalities (25%) and cardiac abnormalities (22%).<sup>1</sup> In a retrospective study of 33 patients with scleromyxoedema from France, the most frequent complications were carpal tunnel syndrome and arthralgia, occurring in 33% and 27% of patients respectively.<sup>5</sup>

### Neurological manifestations

Neurological complications may involve the peripheral nervous system (e.g. carpal tunnel syndrome or peripheral sensory and motor neuropathy) or the central nervous system (e.g. memory loss, vertigo, gait problems, stroke, seizures, psychosis or 'dermato-neuro syndrome').<sup>5,14,15</sup> Carpal tunnel syndrome is thought to be due to either deposition of glycosaminoglycans in the carpal tunnel or to a direct toxic effect in the median nerve.<sup>16</sup> The dermato-neuro syndrome is an occasionally lethal, acute, neurological complication characterized by fever, confusion, dysarthria, lethargy, convulsions and coma.<sup>15,17</sup> The dermato-neuro syndrome is often preceded by flu-like symptoms. In the French series, 18% of patients had dermato-neuro syndrome.<sup>5</sup>

### Rheumatological manifestations

Rheumatological manifestations are characterized by arthralgias or arthritis of the peripheral joints, especially of the hands, with noninflammatory synovial fluids.<sup>18</sup> A severe, destructive polyarthritis resembling rheumatoid arthritis also has been reported.<sup>19</sup> Proximal or generalized weakness due to inflammatory myopathy and fibromyalgia is common and usually occurs several months or years after the onset of skin involvement.<sup>4,20</sup> In these patients, muscle biopsy reveals a necrotizing and vacuolar myopathy; interstitial inflammatory infiltrates are found uncommonly and may cause confusion with polymyositis. A few cases of true dermatomyositis have been described in association with scleromyxoedema.<sup>21</sup> Spontaneous or interferon alfa-induced rhabdomyolysis is an additional rare finding.<sup>22,23</sup>

### Cardiovascular manifestations

Cardiovascular abnormalities with congestive heart failure, myocardial ischaemia, heart block and pericardial effusion may occur.<sup>1,24,25</sup> Valvular mucin deposition has been described in a case report.<sup>26</sup>

### Gastrointestinal manifestations

Dysphagia is the most common gastrointestinal manifestation and is related to oesophageal dysmotility mainly

localized to the upper oesophagus.<sup>27</sup> Dysphagia is most commonly found in patients with an associated myopathy. Nasal regurgitation may also occur.<sup>27</sup>

### Respiratory manifestations

Dyspnoea on exertion is the most common pulmonary finding, due to obstructive or restrictive pathology.<sup>27-29</sup> In addition, hoarseness and aspiration may occur due to laryngeal involvement with decreased epiglottis and vocal cord mobility.<sup>30</sup>

### Renal manifestations

Involvement of the kidney, characterized by a scleroderma renal crisis-like acute renal failure, is a rare event.<sup>31</sup>

### Ocular manifestations

Infrequently, corneal opacities and ectropion are seen.

The pathogenesis of the extracutaneous manifestations of scleromyxoedema is unclear. It has been suggested that mucin deposition in various organs may be the cause, although mucin is not consistently found on autopsy in fatal cases.<sup>32,33</sup> In dermato-neuro syndrome, brain autopsy has not been contributory, and the pathogenic basis of the encephalopathy remains obscure.<sup>15</sup> It has been proposed that an increased blood viscosity with impaired microcirculation due to paraproteinaemia may result in encephalopathy. A pathogenic role for immunoglobulin G (IgG) crossing a damaged blood-brain barrier, mediated by increased IL-6 production, has also been suggested.<sup>15,34</sup>

### Associated disorders

Scleromyxoedema is usually associated with monoclonal gammopathy. The monoclonal protein is most commonly IgG-lambda.<sup>1,5,27,28</sup> However, less frequently, a different monoclonal protein type is present.<sup>27</sup> Patients with scleromyxoedema in the absence of monoclonal gammopathy are considered to have an atypical form of the disease. A mild plasmacytosis may be present in the bone marrow of patients with scleromyxoedema. However, the disease is estimated to progress to multiple myeloma in less than 10% of cases, similar to monoclonal gammopathy of undetermined significance.<sup>4</sup> Anecdotal associations with haematological malignancies (such as Hodgkin and non-Hodgkin lymphomas, Waldenström macroglobulinaemia, lymphoid leukaemia and myelomonocytic leukaemia) or visceral carcinomas have been reported.<sup>1,35-37</sup> Although treatment of the primary cancer may result in the regression of the skin lesions, no clear association with any specific neoplasm has been identified. Most haemolymphoproliferative malignancies in

these patients are iatrogenic and associated with the use of melphalan treatment.<sup>27</sup>

## Clinical course

Scleromyxoedema follows a chronic, progressive and sometimes unpredictable course.<sup>3</sup> Depending on the rapidity of onset and the degree of involvement, patients may be either initially asymptomatic or may notice that skin becomes thick and hard and that the face shows a diffuse induration and coarsening in the forehead lines and lateral portions of the chin. As the disease progresses (usually over the course of years and, occasionally, over the course of several months), a diffuse, sclerodermoid induration with overlying papules, sclerodactyly and decreased motility of the mouth and joints occurs. Spontaneous resolution only very rarely occurs; at least one case of apparent spontaneous resolution has been reported.<sup>38</sup>

Systemic consequences of scleromyxoedema may result in death.<sup>1,32</sup> In a case series in which follow-up was available for 21 patients with scleromyxoedema (mean follow-up time: 33.5 months, range: 2 months to 11 years), at the end of follow-up, five patients (23.8%) died, whereas 12 patients were alive with disease and four patients were alive without disease.<sup>1</sup> Death was caused by extracutaneous complications of scleromyxoedema, including dermato-neuro syndrome (two patients) and myocardial insufficiency due to endocardial mucin deposition (one patient) or by an associated myeloid leukaemia (one patient) or Hodgkin lymphoma (one patient). A better prognosis was reported in a French study in which the overall survival of all 33 patients with scleromyxoedema was 97% at 3 years.<sup>5</sup>

Death also may occur as an adverse effect of treatment. In particular, treatment with melphalan has been associated with death from complications of sepsis and hematological malignancies.<sup>27</sup> In the French study, one patient died of severe sepsis and specific heart involvement following chemotherapy treatment with bortezomib, melphalan and dexamethasone.<sup>5</sup>

## Histopathology

Scleromyxoedema is characterized by a triad of microscopic features that includes<sup>39,40</sup>:

- A diffuse deposit of mucin composed primarily of hyaluronic acid in the upper and mid-reticular dermis; the presence of mucin can be confirmed with an Alcian blue stain (pH 2.5) or a colloidal iron stain and hyaluronidase digestion.
- An increase in collagen deposition.
- A marked proliferation of irregularly arranged fibroblasts.

The epidermis may be normal or thinned by the presence of the underlying mucin and fibrosis; the hair follicles may be

atrophic, and a slight perivascular, superficial, lymphoplasmacytic infiltrate is often present. Sweat gland proliferations are found occasionally.<sup>41</sup> The elastic fibres are fragmented and decreased in number, explaining the clinical presentation of redundant skin folds on a sclerodermoid background ('shar pei sign').<sup>42</sup> Figure 1 shows an anonymized example of a scleromyxoedema face.

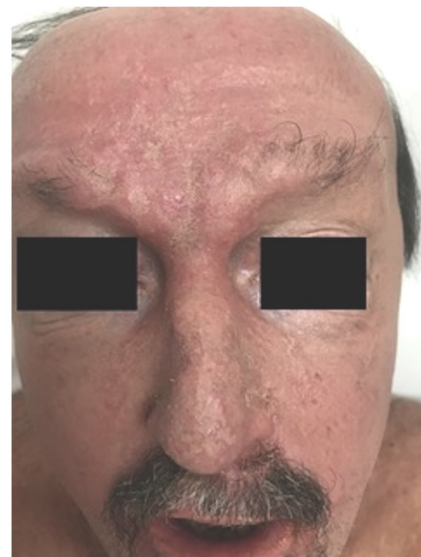An interstitial, granuloma annulare-like pattern has been described in cutaneous biopsy specimens from patients with scleromyxoedema, occurring in approximately 25% of the specimens.<sup>43,44</sup> This histological pattern is characterized by a diffuse, interstitial proliferation of blue-grey histiocytes (CD68+ and CD163+), giant cells and lymphocytes within the superficial and mid-reticular dermis, forming loose granulomas among collagen fibres and mucin deposits.

Histological specimens from extracutaneous sites may demonstrate mucin deposition among myocardial cells and in the walls of myocardial blood vessels as well as in the interstitium of the kidney, lungs, pancreas, adrenal glands and nerves.<sup>25,33</sup> Lymph node involvement with infiltration by numerous fibroblasts surrounded by mucin and collagen deposits has been observed.<sup>45</sup> Mucin has not been found in brain autopsies of patients who died of dermato-neuro syndrome.

## Diagnosis

The diagnosis of scleromyxoedema is based upon the recognition of the following clinicopathological criteria:

- Diffuse/generalized, papular and sclerodermoid eruption.
- Microscopic triad, including mucin deposition, fibrosis, and fibroblast proliferation or, less frequently, an interstitial granulomatous-like pattern.
- Monoclonal gammopathy.



**FIGURE 1** Scleromyxoedema face.

Atypical forms of scleromyxoedema include scleromyxoedema in the absence of monoclonal gammopathy or scleromyxoedema demonstrating an interstitial granulomatous-like pattern on histopathology.

## Skin biopsy

Skin biopsy is the mainstay for diagnosis and should be performed on a group of papules with underlying thickening. Key findings include mucin deposition, fibrosis and fibroblast proliferation.

Immunofluorescence studies are not contributory to the diagnosis of scleromyxoedema and are usually negative.<sup>46</sup> Anecdotally, scanty granular IgG along the epidermal basement membrane and IgG and C1q focally along the connective tissue fibres in the dermis of clinically involved skin have been detected.<sup>47</sup>

## Laboratory tests

The workup of patients with suspected scleromyxoedema should include the following laboratory studies to determine whether the diagnostic criteria are met:

- Serum protein immunoelectrophoresis, immunofixation and serum-free light chain assay to evaluate for monoclonal gammopathy.
- Thyroid studies to rule out myxoedema of thyroid disease.

Serum protein immunofixation generally reveals the presence of a monoclonal protein, most commonly IgG-lambda type.<sup>1</sup> Thyroid function test results are normal.

## Additional tests

There is little value in imaging studies for the diagnosis of scleromyxoedema, although high-resolution cutaneous ultrasonography may become a useful diagnostic and disease activity monitoring tool for skin thickening.

Dermoscopy is nonspecific, showing rice grain-like structures corresponding to papules. Reflectance confocal microscopy features include dermal stellate cells, bright fibres and dark areas, corresponding to the classical triad of fibroblast proliferation, increased collagen deposition and mucin deposits respectively.<sup>48</sup>

Although not necessary for diagnosis, nail fold videocapillaroscopy is normal or nonspecific in scleromyxoedema.<sup>49</sup> This differs from systemic scleroderma, in which megacapillaries and decreased capillary density are characteristic features.

In patients who exhibit symptoms suggestive of extracutaneous disease, the corresponding internal organs should be evaluated. As examples, oesophageal manometry can be useful for evaluating patients with dysphagia,

and pulmonary function studies, including spirometry for forced vital capacity and quantification of diffusing capacity for carbon monoxide, are appropriate for patients with dyspnoea. In dermato-neuro syndrome, lumbar puncture and magnetic resonance imaging typically reveal normal findings; however, electroencephalogram results may be consistent with toxic or metabolic encephalopathy.<sup>15</sup>

## Differential diagnosis

The major disorders in the differential diagnosis of scleromyxoedema are scleroderma (systemic sclerosis) and scleroedema and generalized myxoedema.<sup>50</sup> Other disorders characterized by sclerodermoid skin changes may also enter the differential diagnosis.

## Systemic sclerosis

Characteristic cutaneous findings of systemic sclerosis include skin thickening or hardening that begins on the fingers, hands or face with centripetal extension in the absence of papules. Raynaud phenomenon is present in more than 90% of patients and antecedes the sclerosis of fingers. Associated cutaneous findings include telangiectasia, digital ischemic ulcers and calcinosis. Nailfold capillaroscopy is useful for early diagnosis of systemic sclerosis, showing dilated and giant capillaries, haemorrhages, disorganized vascular arrays, ramified/bushy capillaries and capillary losses. Systemic sclerosis is associated with specific autoantibody profiles, including antitopoisomerase-1 (anti-Scl70) or anti-centromere antibody (for details, please refer to Part I of the Sclerosing Diseases Consensus Statement).

Although patients with scleromyxoedema may have symptoms that mimic scleroderma, such as sclerodactyly, the Raynaud phenomenon (rarely) and oesophageal dysmotility, clinical and laboratory features distinguish the two diseases. The presence of diffuse, waxy papules in linear arrays and in a characteristic distribution that includes the glabella and posterior auricular area, the involvement of the middle portion of the back (always spared in scleroderma), and the presence of an IgG monoclonal gammopathy all favour a diagnosis of scleromyxoedema.

## Scleroedema

Scleroedema (also known as scleroedema adultorum of Buschke) is characterized by a symmetrical, nonpitting induration of the skin that typically begins on the neck and later spreads to the shoulders and upper part of the trunk with occasional erythema. Scleroedema is typically associated with a history of an antecedent upper respiratory infection, diabetes mellitus or blood dyscrasia.<sup>2</sup> The histological findings of scleromyxoedema and scleroedema differ; the fibroblast proliferation that is evident

in histological specimens of scleromyxoedema is absent in scleroedema.<sup>51</sup>

## Generalized myxoedema

Generalized myxoedema is a manifestation of severe hypothyroidism in which mucin is deposited in the dermis, leading to waxiness of the skin. The initial symptoms are subtle and include mental and physical sluggishness, weight gain, constipation, leg cramps, loss of appetite and cold intolerance. The face has a dull expression with oedematous eyelids, broad nose, swollen lips and macroglossia. The skin is pale, cool, waxy and dry with absence of sweating, but the typical papular eruption of scleromyxoedema is missing. A yellowish discoloration of the palms and soles due to carotenemia may appear. Hair and nails are dry and brittle, and a diffuse non-scarring alopecia of the scalp and the lateral third of the eyebrows is common. The serum thyroid-stimulating hormone (TSH) is elevated with low levels of circulating T4. Histopathologically, mucin deposits (mainly perivascular and perifollicular) splay collagen bundles and may extend into the subcutaneous fat, but fibroblasts are not increased in number.

Importantly, scleromyxoedema should be differentiated from the localized variants of lichen myxoedematosus. In the past, the terms 'papular mucinosis', 'lichen myxedematosus' and 'scleromyxoedema' were often used indiscriminately. Although scleromyxoedema and the localized type of lichen myxoedematosus (including subtypes such as acral persistent papular mucinosis, discrete lichen myxoedematosus, papular mucinosis of infancy and nodular lichen myxoedematosus) belong to the same disease spectrum, it is important to make a distinction between the two disorders because of differences in prognosis and the approach to therapy.<sup>2,3</sup> Historically, most patients reported in the literature to have lichen myxoedematosus or papular mucinosis without specification of the disease subtype appear to have had scleromyxoedema with monoclonal gammopathy. Occasionally, patients have overlapping or atypical features and fall in between scleromyxoedema and localized lichen myxoedematosus.<sup>3</sup>

## Treatment

Although treatment of scleromyxoedema is recommended to minimize risk for the development of complications, a paucity of high-quality studies on the efficacy of treatments for scleromyxoedema and an incomplete understanding of the pathogenesis of the disorder have prevented the development of definitive guidelines on the best approach to treatment. No randomized trials have evaluated therapies for scleromyxoedema, and data are primarily limited to case reports and case series due to the rarity of the disease. No specific treatment appears to be uniformly effective or curative, and the relative efficacies of the treatments that have been utilized remain unclear.

As a consequence of the limited data on therapies for scleromyxoedema, opinions vary on the preferred approach to treatment. In all cases, consideration of the risk–benefit ratio of treatment is important for selecting an appropriate therapeutic regimen; both scleromyxoedema and its therapies may induce life-threatening adverse effects.

Complete resolution of the manifestations of scleromyxoedema is the goal of treatment but is not always feasible. Marked improvement in papules and skin thickening is generally considered a successful response of skin disease.<sup>52</sup> Consideration of patient characteristics, patient preferences, clinician experience and treatment accessibility may support the approach to treatment. Of note, successful treatment of scleromyxoedema does not appear to require the resolution of the associated paraproteinaemia.

## Preferred initial therapy

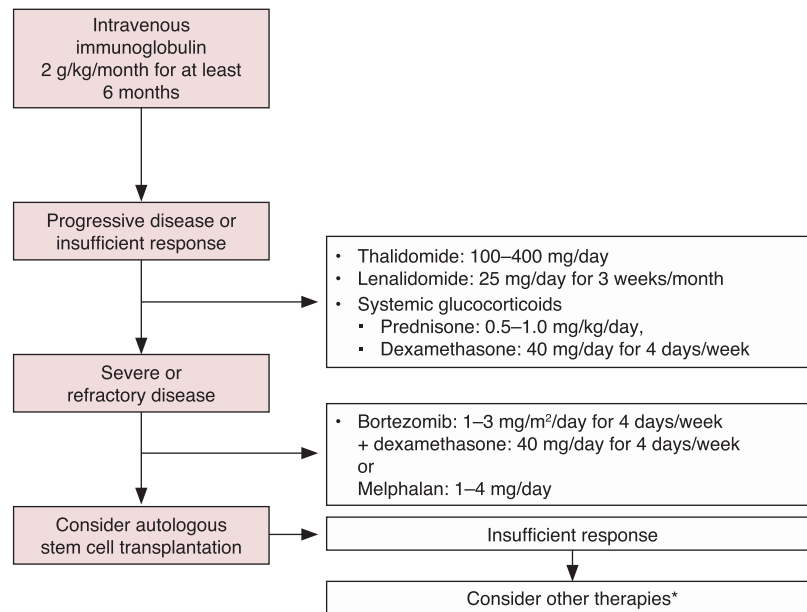
Systemic therapy is the treatment method of choice for patients with scleromyxoedema (Figure 2). Intravenous immunoglobulin (IVIG) is our first choice for therapy, based upon multiple case reports and case series that support its efficacy and the generally well-tolerated nature of this immunomodulatory treatment.<sup>5,52,53</sup> For those patients who cannot receive IVIG, systemic glucocorticoids and immunomodulatory drugs (thalidomide or lenalidomide) are our preferred initial systemic therapies.

In the past, melphalan, a chemotherapeutic agent given with the intent to treat the associated plasma cell dyscrasia, was often considered first-line treatment for scleromyxoedema. However, concerns regarding serious adverse effects, including haematological malignancies and opportunistic infections, contributed to a desire for other less toxic first-line therapies for scleromyxoedema.

### *Intravenous immunoglobulin (IVIG)*

The mechanism by which IVIG improves scleromyxoedema is unclear. Suggested mechanisms focus on the immunomodulatory effects of IVIG, including neutralization of circulating autoantibodies by anti-idiotypic antibodies, functional blockade of fragment crystallizable (Fc) receptors on macrophages and inhibition of fibrosis via modulation of the production of cytokines and cytokine antagonists.<sup>54,55</sup>

*Administration.* IVIG is usually administered at the dose of 2 g/kg per month divided over 2–4 consecutive days per cycle according to the preparation and concentration of IVIG. Improvement in skin and extracutaneous symptoms, especially rheumatological symptoms, often is evident after the first one or two cycles of IVIG.<sup>1,56,57</sup> In our experience, almost all patients exhibit at least partial improvement within 4–6 cycles. Patients with an unsatisfactory response to IVIG after six cycles are typically transitioned to other therapies.



**FIGURE 2** Treatment algorithm for scleromyxoedema. \*Other therapies include topical betamethasone and topical dimethyl sulfoxide, oral isotretinoin, acitretin, interferon- $\alpha$ , hydroxychloroquine, cyclosporine, chemotherapeutic agents, including cyclophosphamide, methotrexate, chlorambucil and 2-chlorodeoxyadenosine. UVA-1 or PUVA phototherapy, Grenz ray and total skin electron-beam therapy.

Lower doses of IVIG may also be effective. A patient with skin-limited disease who had failed to respond to systemic glucocorticoids, extracorporeal photopheresis and interferon had a reduction in clinical findings within two cycles of IVIG given at a dose of 0.5 g/kg over five days at 4-week intervals.<sup>56</sup>

Although remissions persisting for a few months to three years after cessation of IVIG infusions have been reported, the response to IVIG is usually transient.<sup>28,57,58</sup> Maintenance IVIG cycles every 6–8 weeks are generally required to maintain remission.<sup>57</sup> Usually, IVIG is administered over 2–4 days at a dose of 2 g/kg of IVIG every six weeks or 1.5 g/kg of IVIG every four weeks.

Drawbacks of IVIG treatment are its high cost and the time-consuming administration. The use of more concentrated IVIG, reducing the time of administration to two days, has improved the management of the disease. Possible adverse effects are skin flushes, vesicular or bullous dermatitis of the hands, arthralgias, myalgias, fever, headache, aseptic meningitis, thoracic or abdominal pain, nausea and tachycardia. Myocardial ischaemia and death secondary to suspected myocardial infarction have been reported in scleromyxoedema patients with known cardiac risk factors during treatment with IVIG.<sup>1,59</sup> However, the adverse effects experienced by patients receiving IVIG for scleromyxoedema generally have been mild and self-limited.<sup>60</sup>

**Efficacy.** Data on the efficacy and safety of IVIG are primarily limited to case reports and case series; no randomized trials have been performed.<sup>1,5,6,28</sup> Examples of

published reports that have offered support for the efficacy of IVIG for this disease include:

- In a retrospective study, 13 of 31 patients (42%) with scleromyxoedema (without features of dermato-neuro syndrome or mucinous cardiac involvement) treated with IVIG (2 g/kg monthly for the first six months) as a first- or second-line therapy achieved a complete clinical response.<sup>5</sup> Patients were treated with IVIG for a median of 16 months.
- In a review of eight adults with scleromyxoedema who were treated with monthly cycles of IVIG (2 g/kg per cycle divided over 2–5 days), all achieved a response (2—complete response and 6—partial response) after up to six cycles of IVIG.<sup>28</sup> Treatment was followed by maintenance therapy every 6–12 weeks as needed.
- In a multicentre, retrospective study of 30 patients with scleromyxoedema, three of the six patients treated with IVIG (2 g/kg per monthly cycle) achieved complete clinical remissions.<sup>1</sup> The three remaining patients achieved partial responses.

In the first study, a complete clinical response was defined as complete clinical improvement from baseline. In the latter two studies, complete responses were defined as an absence of systemic symptoms or skin findings of scleromyxoedema, and partial responses consisted of a decrease in skin changes and improvement in systemic symptoms. In these and other reports, responders to IVIG have included both patients who received IVIG as initial treatment and patients who had previously failed other therapies.<sup>1,5,28,57,61</sup>

## Failure of initial therapy

In the few cases in which treatment with IVIG is not an option or yields an insufficient response, we institute other therapies. Systemic glucocorticoids and thalidomide are our preferred next-line treatments. Systemic glucocorticoids and thalidomide can be given alone. More often, we add one of these agents to IVIG therapy because of the favourable results we have observed with combination therapy.

Selection between systemic glucocorticoids and thalidomide is based upon consideration of factors such as patient co-morbidities, tolerability, drug availability and clinician comfort. Most often, we use systemic glucocorticoids first; only if the response is insufficient do we begin thalidomide, as adverse events under steroids are usually better controlled than those under thalidomide (e.g. irreversible peripheral polyneuropathy).

Patients with severe disease who cannot be successfully managed with IVIG, thalidomide, and/or systemic glucocorticoids are candidates for trials of more aggressive interventions, where such trials are available.

### *Systemic glucocorticoids*

Systemic glucocorticoids have been used for scleromyxoedema as monotherapy or in conjunction with chemotherapeutic agents.<sup>62,63</sup> It is postulated that benefit from systemic glucocorticoids may result from immunosuppressive and antifibroblast effects of these agents.<sup>64</sup>

*Administration.* Our preferred regimen for systemic glucocorticoid therapy is prednisone (0.5–1 mg/kg per day) until the desired therapeutic effect is reached. Responses usually occur within four weeks. Then, we begin to slowly taper the glucocorticoid dose to the lowest dose necessary to maintain the response to treatment. If patients failed to respond within 4–6 weeks, we consider treatment ineffective and typically transition to thalidomide.

*Efficacy.* Data on the efficacy of systemic glucocorticoids in scleromyxoedema are limited to case reports. Prednisone (0.5–1 mg/kg per day), prednisolone (0.3–0.5 mg/kg per day) and oral high-dose dexamethasone (40 mg once daily for four days per week during three consecutive weeks each month) have been associated with improvement in cutaneous manifestations of scleromyxoedema in individual patients.<sup>64–66</sup> The associated paraproteinaemia may or may not improve in patients in whom systemic glucocorticoid therapy induces remission of scleromyxoedema.<sup>66,67</sup> Failure of systemic glucocorticoid therapy to improve scleromyxoedema has also been reported.<sup>1</sup>

### *Immunomodulatory drugs (thalidomide or lenalidomide)*

The mechanism of action of thalidomide in scleromyxoedema is unknown. Immunomodulatory effects on proinflammatory and profibrotic cytokines and antiangiogenic properties may contribute to inhibition of fibrosis.<sup>68</sup>

Lenalidomide, a thalidomide derivative with a more favourable adverse effect profile, may be a reasonable alternative to thalidomide. Disadvantages of lenalidomide compared with thalidomide include higher cost and less data on the efficacy of this therapy.

*Administration.* Treatment with thalidomide should begin at a dose of 50–100 mg per day, then increase slowly up to 150–400 mg per day according to clinical response and tolerance. Clinical improvement is expected within 2–3 months, and a change in therapy is appropriate for patients who exhibit no improvement within this period. Once a satisfactory response to thalidomide is achieved, the lowest effective dose is used for maintenance therapy. Teratogenicity and peripheral neuropathy are adverse effects of thalidomide that can limit the use of this therapy and other adverse effects include drowsiness, constipation, thrombosis and leukopenia. Patients should be monitored for the development of peripheral neuropathy during treatment. Lenalidomide, a haematological agent, is usually used at a dose of 10–25 mg per day for three weeks per month, starting with the lower dose. Once response is achieved, the lenalidomide dose can be reduced to the lowest dose effective for maintaining improvement.

Examples of potential adverse effects of lenalidomide include teratogenicity, thrombocytopenia, neutropenia and thrombosis.

*Efficacy.* Multiple case reports have documented improvement in the cutaneous manifestations of scleromyxoedema following treatment with thalidomide.<sup>69–74</sup> Improvement in systemic manifestations<sup>74</sup> and serum paraprotein levels<sup>69</sup> have also been reported in some patients. Thalidomide may be a useful adjunct to IVIG therapy; the addition of thalidomide to IVIG appeared to be useful for decreasing the frequency of IVIG treatment in a case report.<sup>68</sup>

A few case reports and series have documented the use of lenalidomide. In a retrospective study, treatment of three patients with IVIG-refractory scleromyxoedema with lenalidomide, dexamethasone and IVIG was associated with partial clinical responses and complete haematological responses in all patients.<sup>5</sup> In case reports, lenalidomide (25 mg per day for three weeks per month) appeared beneficial when used in combination with IVIG in one patient<sup>75</sup> but failed to induce clinical improvement when used in combination with dexamethasone in another patient.<sup>12</sup>

## Severe and refractory disease

Patients who fail to achieve sufficient improvement with the therapies above may benefit from interventions aimed at treating the associated plasma cell dyscrasia.

Examples of therapeutic options include bortezomib, a proteasome inhibitor, with dexamethasone, autologous stem cell transplantation and melphalan. Data are limited

on the efficacy of these therapies for cutaneous and extracutaneous manifestations of scleromyxoedema. In addition, the response to these treatments is variable and relapse may occur. Thus, the risks associated with these therapies must be considered carefully prior to treatment.

Our typical approach to severe disease that has failed to respond to IVIG, systemic glucocorticoids and immunomodulatory drugs starts with bortezomib in addition to dexamethasone therapy. Poor responders are candidates for autologous stem cell transplantation. We generally avoid melphalan because of concern for serious haematological toxicity, including malignancy.

#### *Bortezomib and dexamethasone*

Combination therapy with bortezomib and dexamethasone has been associated with rapid improvement in cutaneous manifestations and constitutional symptoms of scleromyxoedema in case reports, including a patient who relapsed after autologous stem cell transplantation.<sup>12,76</sup> A successful response was also observed in a patient treated with bortezomib and dexamethasone in combination with thalidomide.<sup>11</sup>

Our typical regimen involves bortezomib given at a dose of 1.3 mg/m<sup>2</sup> (maximum of 2 mg per dose) on days 1, 8, 15 and 22. Dexamethasone (40 mg per dose) is given on days 1, 8, 15 and 22. A total of six cycles are given over a period of six months. In very refractory cases, thalidomide may be added, given at a dose of 100 mg per day for the first 14 days followed by 200 mg per day for the next seven days, similar to a protocol used for myeloma.

#### *Autologous stem cell transplantation*

Multiple cases of scleromyxoedema treated with autologous stem cell transplantation have been reported since the initial report of a complete remission in 2001.<sup>77</sup> In a review of 17 reported cases of scleromyxoedema treated with autologous stem cell transplantation published between 2001 and 2011, complete remissions (resolution of all clinical symptoms, skin abnormality and serum paraprotein) were attained by 10 patients (59%) and partial remissions were attained by five patients (29%).<sup>78</sup> However, only two of the complete responders remained in remission after follow-up periods ranging between 14 and >60 months. Allogeneic haematopoietic cell transplant has also been tried with success in a patient with refractory disease.<sup>79</sup>

#### *Melphalan*

Although melphalan was often considered a first-line treatment for scleromyxoedema in the past, the potential for drug-related serious adverse events, and the efficacy achieved with the aforementioned drugs, limits the use of this agent. A review of 17 patients who received melphalan for scleromyxoedema (1–4 mg per day or cyclic therapy) at a single medical centre found that although 12 patients had improvement of skin disease with therapy, improvement was temporary in eight patients and nine patients died of haematological

malignancy or septic complications that were considered related to therapy.<sup>27</sup>

## Dermato-neuro syndrome

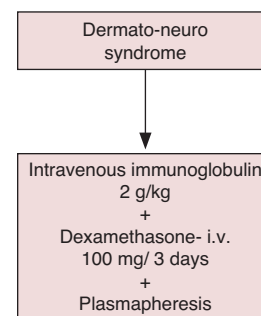
The approach to patients with dermato-neuro syndrome is not standardized, and various treatments have seemed to yield benefit in case reports. Examples include IVIG,<sup>61</sup> systemic glucocorticoids plus plasmapheresis or IVIG,<sup>17,80</sup> systemic glucocorticoids plus cyclophosphamide and plasmapheresis,<sup>5,14</sup> melphalan plus IVIG and bortezomib plus dexamethasone.<sup>81</sup> Spontaneous improvement also has been reported.<sup>15</sup>

Our typical initial approach consists of IVIG (2 g per kg per month) with dexamethasone pulse therapy (intravenous dexamethasone [100 mg per day] given for three consecutive days per month). This may be followed by the addition of plasmapheresis (every other day for 10 days) for patients who do not improve within two cycles of IVIG and dexamethasone therapy (Figure 3).

## Other therapies

Case reports have documented clinical improvement in patients treated with topical betamethasone and topical dimethyl sulfoxide,<sup>82</sup> topical and intralesional corticosteroid therapy,<sup>83</sup> oral isotretinoin,<sup>84,85</sup> acitretin,<sup>1</sup> interferon-alfa,<sup>86</sup> hydroxychloroquine,<sup>1</sup> cyclosporine,<sup>87</sup> and chemotherapeutic agents, including cyclophosphamide,<sup>88</sup> methotrexate,<sup>20,89</sup> chlorambucil,<sup>90</sup> and 2-chlorodesoxyadenosine.<sup>91</sup> The efficacies of these agents for scleromyxoedema remain to be confirmed. Of note, treatment with interferon-alfa was associated with worsening of symptoms in a woman with localized lichen myxoedematosus.<sup>92</sup> Some case reports have suggested that JAK inhibition and dupilumab may also be used.

Ultraviolet A1 (UVA1) or psoralen plus ultraviolet A (PUVA) phototherapy,<sup>93</sup> Grenz ray<sup>32,94</sup> and total skin



**FIGURE 3** Treatment algorithm for dermato-neuro syndrome. Here, the authors present our typical approach for treating dermato-neuro syndrome, though treatment approaches for this syndrome are not yet standardized. Other therapies may be considered.

electron beam therapy<sup>95</sup> have also been reported to improve cutaneous manifestations of scleromyxoedema in case reports. The therapeutic mechanisms of the different phototherapy modalities with their antifibrotic components in skin conditions including scleromyxoedema have been recently reviewed.<sup>96</sup> These therapies do not have an impact on paraproteinaemia and systemic involvement. Of note, accidental excessive exposure to ultraviolet B (UVB) has appeared to exacerbate the disease in one patient.<sup>97</sup>

Tumour necrosis factor (TNF)-alpha inhibitors may not be useful. TNF-alpha has been suggested as a profibrotic cytokine that may be implicated in the pathogenesis of scleromyxoedema, and a patient in whom IVIG lost efficacy failed to respond to infliximab.<sup>98</sup>

#### *Cosmetic interventions*

Case reports suggest that facial disfigurement can be treated with dermabrasion plus surgery or carbon dioxide laser with good cosmetic results.<sup>99,100</sup> These procedures of course do not affect systemic manifestations of scleromyxoedema.

### **Prognosis and follow-up**

Scleromyxoedema is a disease with an unpredictable but usually progressive and disabling course in the absence of successful treatment. Even when therapy is successful, long-term maintenance therapy usually is required since relapse commonly occurs upon the discontinuation of treatment. Death may result from complications of extracutaneous involvement or adverse effects of therapy. Because of the various cutaneous and extracutaneous manifestations of scleromyxoedema, a multispecialty team often is needed for the optimal management of these patients. Depending on the manifestations present, dermatologists, haematologists, cardiologists, pulmonologists, gastroenterologists, hand surgeons and other specialists can be valuable for managing affected patients.

The unpredictable course of scleromyxoedema, the variable response to treatment and the common occurrence of relapse demand close, long-term follow-up of these patients. We usually reassess patients once per month with a full skin examination, review of systems and re-evaluation of the therapeutic regimen. Serological studies, including assessment of the status of the associated monoclonal gammopathy, are not useful for monitoring disease activity.

Patients should be cautioned that development of neurological symptoms (e.g. dysarthria) and flu-like illness may be the initial signs of dermato-neuro syndrome. Patients with such symptoms should be admitted to the hospital for close observation, evaluation and eventually admission to the intensive care unit.

Follow-up data on patients treated for scleromyxoedema are limited, but relapse after treatment appears to be common. Most patients treated with IVIG require continued

therapy to remain in remission.<sup>28,57</sup> Frequent relapses have also been reported following autologous bone marrow transplantation and melphalan therapy.<sup>27,78</sup> No treatment has been identified that definitively cures the disease.

### **Recommendations**

- Scleromyxoedema is an uncommon, diffuse/generalized, papular and cutaneous eruption that usually occurs in association with monoclonal gammopathy and may have accompanying systemic features. The disorder typically affects adults. There is no sex predilection. The pathogenesis of scleromyxoedema is unknown, but circulating cytokines, such as IL 1, TNF-alpha, TGF- beta and IL-4, known to stimulate glycosaminoglycan synthesis and fibroblast proliferation in the skin, seem to play a role.
- The cutaneous manifestations of scleromyxoedema consist of widespread, waxy papules and indurated plaques. Progressive cutaneous involvement can lead to decreased motility of the mouth and joints. Extracutaneous involvement in scleromyxoedema can present with a variety of manifestations. Neurological, musculoskeletal, cardiac, gastrointestinal, respiratory or renal abnormalities may develop.
- The clinical course of scleromyxoedema is chronic and progressive. Cutaneous and extracutaneous involvement can lead to significant morbidity. Death may result from complications related to extracutaneous involvement or adverse effects of therapy.
- The diagnosis of scleromyxoedema is based upon recognition of consistent clinical, pathological and laboratory findings. The presence of the following features is supportive of the diagnosis:
  1. Diffuse/generalized, papular and sclerodermoid eruption.
  2. Microscopic triad, including mucin deposition, fibrosis and fibroblast proliferation, or, less frequently, an interstitial granulomatous-like pattern.
  3. Monoclonal gammopathy.
- There is a paucity of data on the treatment options for scleromyxoedema. The available data consist primarily of case reports and case series. Thus, there are no definitive consensus on the best approach to treatment.
- Patients with scleromyxoedema generally require systemic therapy. We suggest IVIG as initial treatment (Grade 2C). Systemic glucocorticoids and immunomodulatory drugs (thalidomide or lenalidomide) are alternative treatment options that may also be used in conjunction with IVIG therapy.
- Patients who fail to respond to IVIG, systemic glucocorticoids or immunomodulatory drugs may benefit from other therapies. Examples of treatment options for severe and refractory disease include bortezomib plus dexamethasone, autologous stem cell transplantation and melphalan. The risk-benefit ratios of treatment must be carefully considered prior to therapy.

- Recurrence of scleromyxoedema is common after withdrawal of an effective therapy. Long-term maintenance treatment usually is required, and close clinical follow-up is necessary.

## SCLEROEDEMA

### Epidemiology and pathogenesis

Scleroedema (of Buschke) is a rare scleromucinous connective tissue disease. Scleroedema occurs in individuals of all ages and ethnicities, and contradictory to Buschke's original description as 'scleredema adultorum', more than 50% of patients are aged under 20 years.<sup>101</sup>

The exact prevalence and incidence of scleroedema are not known. Prospective studies showed prevalence of 2.5%–14.0% in patients with diabetes mellitus,<sup>102,103</sup> suggesting that scleroedema is an underrecognized disease.

Three types of scleroedema can be distinguished, according to their association with preceding or underlying conditions:

- Type 1 scleroedema (the classic 'Buschke' type, 55% of cases) usually follows a febrile infection, especially streptococcal or viral respiratory tract infection,<sup>104</sup> and affects mainly children and women.<sup>105</sup> Recently, one case has been reported on scleroedema after developing SARS-CoV2 infection.<sup>106</sup>
- Type 2 scleroedema is associated with haematological diseases like paraproteinaemia including monoclonal gammopathy,<sup>107–109</sup> multiple myeloma<sup>110–112</sup> and amyloidosis.<sup>113</sup> Haematological diseases often develop years after onset of scleroedema.
- Type 3 scleroedema was named 'scleredema diabeticorum' by Krakowski and colleagues,<sup>114</sup> and manifests mostly in men with diabetes mellitus.<sup>115</sup>

Scleroedema can be associated with several other systemic diseases like rheumatoid arthritis,<sup>116–118</sup> ankylosing spondylitis,<sup>108</sup> Sjögren's syndrome,<sup>118</sup> dermatomyositis,<sup>119</sup> hyperparathyroidism,<sup>120,121</sup> hypothyroidism,<sup>122</sup> Waldenström's macroglobulinaemia, anaphylactoid purpura, primary biliary cirrhosis,<sup>123</sup> IgA deficiency,<sup>124</sup> human immunodeficiency virus infection,<sup>125</sup> and pyoderma gangrenosum.<sup>126</sup> Cases of concomitant neoplasms have been reported, such as malignant insulinoma,<sup>127</sup> gall bladder carcinoma,<sup>128</sup> carcinoid tumour,<sup>129</sup> adrenocorticotropic hormone-producing pituitary tumour<sup>130</sup> and ovarian/breast carcinoma.<sup>131,132</sup>

In type 1 and 2 scleroedema, women are affected almost twice as frequently as men. In contrast, in type 3 scleroedema, the male-to-female ratio is considered to be 10:1.<sup>133</sup>

Very little is known about pathophysiology of scleroedema. Excessive production of mucin (heavily glycosylated high-molecular weight proteins) and collagens by fibroblasts from the reticular dermis is characteristic of scleroedema.

This may be provoked by diverse stimuli, including infections, inflammatory processes, hypoxia, microvascular damage, drugs, toxins, genetic factors and hyperinsulinism or chronic hyperglycaemia.<sup>104,134–136</sup>

### Diagnostic procedures

#### Clinical presentation

The clinical symptoms of scleroedema include cutaneous and extracutaneous findings, depending on the type of the disease.<sup>104,133,134</sup>

All three types of scleroedema manifest as a symmetrical hardening of the skin with woody, non-pitting, indurated plaques which mostly starts on the neck and spreads to face, upper part of the trunk, shoulders and arms, but spares fingers.<sup>135,137,138</sup> This induration can range from mild, often not noticed skin thickening, to more extensive skin hardening with reduced mobility, and may include a transient erythematous eruption.<sup>105</sup>

There is no specific clinical score for scleroedema. The mRSS (developed for systemic sclerosis<sup>139</sup>) may be used to evaluate the severity of skin involvement and to document its activity.

Type 1 scleroedema starts suddenly 1–3 weeks after respiratory infection with fever and usually resolves in a few months. Types 2 and 3 are mostly slowly progress and persist for years. Cases with limited periorbital manifestation<sup>140</sup> and one unusual case of unilateral scleroedema<sup>141</sup> have been reported.

Extracutaneous involvement is possible in all three forms of scleroedema and include serositis, arthropathy, myositis, dysphagia, dysphonia, parotitis, ophthalmoplegia or cardiomyopathy.<sup>142</sup>

#### Histopathology

A deep skin biopsy that includes subcutaneous fat is required to confirm the diagnosis and to exclude other sclerosis-like disorders.

The following histopathological findings are characteristic for scleroedema:

- The epidermis is usually not involved.
- The dermis is up to four times thicker than normal, due to enlarged collagen bundles in deep reticular dermis with wide, clear, mucin-filled spaces between them.<sup>104,125,143</sup> Mucin deposits represent non-sulphated acid mucopolysaccharides, mainly hyaluronic acid, stainable with Alcian blue dye, colloidal iron or toluidine blue. In cases of systemic disease, mucin deposits can also be found in muscles and heart. In some cases, multiple biopsies are required in order to detect mucin deposits within the dermis, and therefore, the absence of mucin deposits does not exclude the diagnosis of scleroedema.

- No proliferation of fibroblast can be detected in dermis from skin biopsies in patients with scleroedema, in contrast to scleromyxoedema.
- The subcutaneous fat is sometimes replaced by collagen fibres.<sup>104</sup>
- Skin appendages are usually preserved (unlike in systemic sclerosis). However, some authors have reported the loss of eccrine glands.<sup>125,144</sup>

### Laboratory parameters

Fasting glucose, HbA1c, leukocyte count (lymphocytes), serum protein electrophoresis, serum and urine immunofixation and AST throat cultures should be performed to screen for diabetes and monoclonal gammopathy.<sup>144</sup> If paraproteinaemia becomes apparent, additional investigations should be discussed, including cytofluorometry analysis (for the detection of B-cell lymphoproliferation). Antinuclear antibody (ANA) testing is negative, in contrast to most cases with systemic sclerosis.

### Imaging

A durometer or an ultrasonography measurement of skin thickness may be performed in order to evaluate the severity and to monitor the disease.<sup>145,146</sup> Range of motion, especially within the shoulder girdle, is well suited to monitoring disease. In cases of systemic involvement, specific diagnostic examinations are required (e.g. pulmonary function tests, ultrasonography of internal organs, including the heart, liver or spleen, oesophageal manometry, radiography or ultrasonography of bones and joints). In cases of monoclonal gammopathy or clinical evidence of enlarged lymph nodes, chest and abdomino-pelvic computerized tomography scan, positron emission tomography scan, lumbar and dorsal magnetic resonance imaging and/or myelogram/osteomedullary biopsy are the methods of choice.

In summary, the diagnosis of scleroedema is made clinically, with the definitive diagnosis confirmed by histopathology. A typical woody thickening of the skin which starts on the neck or upper trunk and spares acral locations (hands are not involved), history of a preceding infection, underlying paraproteinaemia or diabetes and accumulation of mucopolysaccharides in the microscopic evaluation are the main diagnosis criteria of scleroedema.

### Differential diagnoses

Typical symmetrical localisation of skin hardening and histological features like the characteristic thickness of the dermis with the accumulation of mucin distinguish scleroedema from other sclerotic disorders.<sup>147,148</sup> Very rarely, a combination of sclerotic disorders in one patient is possible.<sup>149,150</sup> Differential diagnoses are summarized in Table 1.

### Treatment

The evidence for therapeutic effects in scleroedema is based on retrospective studies, case reports and case series. The lack of randomized controlled trials for scleroedema creates difficulty in concluding the best treatment regimens, optimum dose and long-term efficacy.

Therapy is needed in patients with reduced mobility, due to skin hardening or systemic involvement. In addition, appropriate treatment should be performed if an associated condition could be identified (infection in type 1 scleroedema, a lymphoproliferative disorder in type 2, or diabetes mellitus in type 3).

Physical therapy is recommended for all three types of scleroedema, in order to improve the mobility of patients. Escalation of therapy in resistant cases of scleroedema is possible through the use of phototherapy (PUVA, UVA1 and narrowband UVB)<sup>151–156</sup> or drug treatment (Table 2). Table 2 summarizes the treatment options for scleroedema. The risk-benefit ratio must be analysed for each patient before initiating therapy. Further studies are needed to explore the evidence level of suggested treatments.

### Clinical course and prognosis

Scleroedema leads to decreased quality of life and higher morbidity, but only in sporadic cases, and to increased mortality due to cardiac or lung involvement.<sup>157</sup>

The efficacy of treatments for scleroedema can be assessed using the mRSS, Health Assessment Questionnaire (HAQ), the range of motion of involved joints and the Dermatology Life Quality Index (DLQI).

Type 1 scleroedema associated with a preceding infection is characterized by a good prognosis and even spontaneous resolution. The active phase lasts 2–8 weeks and is followed by a resolution in a couple of months to 2 years.

Type 2 scleroedema (which is associated with blood dyscrasia) should be carefully followed up. The prognosis is poor; the lesions are persistent with possible systemic involvement leading to life-threatening complications. In patients with or without identified lymphoproliferation, leukocyte count (lymphocytes), serum protein electrophoresis and serum and urine immunofixation, as well as a thorough physical examination for lymph node enlargement and/or hepato-splenomegaly, should be performed annually. If monoclonal gammopathy of unspecified significance is detected, the risk of multiple myeloma or another related malignancy is about 1% per year.

Type 3 (diabetic) scleroedema has a poor prognosis, with a chronic progressive course and systemic complications. It also requires follow-up of patients with monitoring of the metabolic state (fasting blood glucose, HbA1c, and body weight). Sleep apnoea syndrome is common, and specific diagnostic tests are necessary to confirm the disorder. With the advent of new antidiabetic drugs and the ability to rigorously regulate blood glucose levels, more frequent and

**TABLE 1** Differential diagnoses of scleroedema.

Differential diagnosis	Distinguishing features
Systemic sclerosis	<ul style="list-style-type: none"> <li>• Skin thickening typically begins at the fingertips, progressing to involve the hands and feet (spared in scleroedema)</li> <li>• Raynaud's phenomenon, abnormal nail fold capillaries and ANA (absent in scleroedema)</li> <li>• No mucin deposits</li> </ul>
Scleromyxoedema	<ul style="list-style-type: none"> <li>• Induration of the skin progresses acrally and typically forms characteristic large folds or firm papules, often in linear order (unlike in scleroedema)</li> <li>• Systemic complications and the association with monoclonal gammopathy and mucin deposits are common in both diseases</li> </ul>
Myxoedema	<ul style="list-style-type: none"> <li>• Clinical and serological thyroid function abnormalities</li> </ul>
Eosinophilic fasciitis	<ul style="list-style-type: none"> <li>• Induration in areas corresponding to the anatomic localization of the fascia on the trunk and extremities (unlike in scleroedema)</li> <li>• Depression along the course of the superficial veins (Groove sign)</li> <li>• Eosinophilia (absent in scleroedema)</li> <li>• No mucin deposits<sup>a</sup></li> </ul>
Cutaneous amyloidosis	<ul style="list-style-type: none"> <li>• Characteristic amyloid deposits found in the affected tissues when stained with Congo red dye<sup>b</sup></li> </ul>
Lymphoedema	<ul style="list-style-type: none"> <li>• The removal or damage to lymph nodes is common in the medical history</li> <li>• Affects the extremities; is most strongly expressed acrally (unlike in scleroedema)</li> <li>• Keratinocyte hypoproliferation, condensed dermal collagen and mononuclear perivascular infiltrate (unlike in scleroedema)</li> <li>• No mucin deposits</li> </ul>
Cardiac or renal oedema	<ul style="list-style-type: none"> <li>• Oedema is usually non-solid, 'pitting' and is likely to occur in acral locations (unlike in scleroedema)</li> <li>• Symptoms of heart or renal failure</li> <li>• Different histopathological features</li> <li>• No mucin deposits</li> </ul>
Radiotherapy-induced skin thickening	<ul style="list-style-type: none"> <li>• Previous radiotherapy<sup>c</sup></li> <li>• Lesions are usually limited to the exposed area</li> <li>• No mucin deposits</li> </ul>
Graft-versus-host disease	<ul style="list-style-type: none"> <li>• History of haematopoietic cell transplantation</li> <li>• No mucin deposits</li> </ul>

Abbreviation: ANA, antinuclear antibodies.

<sup>a</sup>The biopsy should be sufficiently deep to reach the fascia.

<sup>b</sup>Amyloidosis, however, may be a consequence of advanced lymphoproliferative disease as the underlying cause of type 2 scleroedema.

<sup>c</sup>Scleroedema after radiation treatment is possible.<sup>158</sup>

**TABLE 2** Treatment of scleroedema.

Treatment indication	Therapeutic measures
Treatment of the identified cause:	
Type 1	<ul style="list-style-type: none"> <li>• Antimicrobial agents, if indicated</li> </ul>
Type 2	<ul style="list-style-type: none"> <li>• Therapy of the identified lymphoproliferative disorder in consultation with a haematologist</li> </ul>
Type 3	<ul style="list-style-type: none"> <li>• Antidiabetics, insulin (blood glucose self-monitoring)</li> </ul>
Treatment for all three types of scleroedema	<ul style="list-style-type: none"> <li>• Physical therapy<sup>a</sup></li> </ul>
In cases with persistent skin hardening with reduced mobility or systemic involvement	<ul style="list-style-type: none"> <li>• First line: medium-to high-dose UVA1 or PUVA<sup>b</sup></li> <li>• Second line: methotrexate (<math>\pm</math>glucocorticoids, except for diabetic patients)</li> <li>• Advanced line: other treatments<sup>c</sup></li> </ul>

<sup>a</sup>To increase the range of motion of involved joints and respiratory rehabilitation.<sup>159</sup>

<sup>b</sup>For more information, please refer to the Section I—Localized scleroderma.

<sup>c</sup>If methotrexate fails or is contraindicated, based on a risk–benefit approach, the following alternative treatments can be proposed: glucocorticoids, systemic or intralesional,<sup>160</sup> cyclosporine,<sup>161,162</sup> prostaglandin E1,<sup>163</sup> intravenous immunoglobulins,<sup>164,165</sup> high-dose penicillin,<sup>166</sup> factor XIII infusion,<sup>167</sup> cyclophosphamide,<sup>112</sup> tranilast,<sup>168</sup> thalidomide,<sup>169</sup> bortezomib,<sup>110</sup> radiotherapy,<sup>170</sup> extracorporeal shock wave therapy,<sup>171</sup> electron-beam radiotherapy<sup>172</sup> and extracorporeal photopheresis.<sup>173</sup>

marked improvements have been seen in type 3 scleroedema. As diabetic scleroedema is under-recognized, there is a need for appropriate education.

## Recommendations

- The diagnosis of scleroedema is made clinically: a typical woody thickening of the skin which starts on the neck or upper trunk and spares acral locations (hands are not involved), history of a preceding infection, underlying paraproteinaemia or diabetes. A histopathological examination (mucin deposits in dermis) is performed to confirm a definitive diagnosis.
- Scleroedema type 1 does not usually require treatment, as it is self-limited and usually resolves in a short period of time. If the patient wishes to have therapy, physical therapy (and sometimes also phototherapy) can be recommended.
- If associated conditions are identified (infection in type 1 scleroedema, lymphoproliferative disorder in type 2 or diabetes mellitus in type 3), appropriate therapy should be performed.
- Patient follow-up in persistent scleroedema is needed to screen for paraproteinaemia, systemic complications and co-morbidities; a follow-up every 3 months is recommended for patients with progressing disease, and a yearly follow-up is recommended for those with stable disease.
- No specific therapy for scleroedema is available, although numerous methods have been proposed based

on retrospective studies, case reports and case series (low evidence). The recommended first-line treatment is phototherapy. If this fails, methotrexate is recommended.

- Randomized controlled trials for scleroedema should be performed in the future to identify the best treatment regimens, optimum dose and long-term efficacy of the therapy.

## Methods

The current consensus statement on diagnosis and treatment of sclerosing diseases of the skin was developed through discussion with a panel of 30 international experts in dermatology, rheumatology and related fields in an iterative process. Multiple rounds of emails were shared to gather individual opinions and recommendations on the topic in question, allowing participants to review and revise their responses until a consensus was reached.

## AFFILIATIONS

- <sup>1</sup>Department of Dermatology, Medical University of Vienna, Vienna, Austria
- <sup>2</sup>Department of Dermatology, Ordensklinikum Linz Elisabethinen, Linz, Austria
- <sup>3</sup>Faculty of Medicine, Johannes Kepler University, Linz, Austria
- <sup>4</sup>Department of Dermatology, Venereology and Allergology, HELIOS St. Elisabeth Klinik Oberhausen, University Witten-Herdecke, Oberhausen, Germany
- <sup>5</sup>Department of Dermatology and Venereology, University of Cologne, Cologne, Germany
- <sup>6</sup>Vita Salute University IRCSS San Raffaele Hospital, Milan, Italy
- <sup>7</sup>Center for Rheumatology, Royal Free and University College Medical School, London, UK
- <sup>8</sup>Service de Médecine Interne, Centre de Référence Maladies Auto-Immunes et Systémiques Rares d'Ile de France, APHP-CUP, Hôpital Cochin, Paris, France
- <sup>9</sup>Institut Cochin, Université de Paris Cité, Paris, France
- <sup>10</sup>Laboratories for Experimental Rheumatology and Academic Division of Clinical Rheumatology, Department of Internal Medicine DiMI, University Medical School of Genoa, IRCCS San Martino Genoa, Genova, Italy
- <sup>11</sup>Department of Internal Medicine, Ghent University, Ghent, Belgium
- <sup>12</sup>Department of Rheumatology, Ghent University Hospital, Ghent, Belgium
- <sup>13</sup>Unit for Molecular Immunology and Inflammation, VIB Inflammation Research Center (IRC), Ghent, Belgium
- <sup>14</sup>Fondazione di Medicina Molecolare e Terapia Cellulare, Università Politecnica delle Marche, Ancona, Italy
- <sup>15</sup>Department of Dermatology, Hôpital Saint-Louis, Université Paris Cité, Paris, France
- <sup>16</sup>Department of Dermatology, University Hospital of Aarhus, Aarhus, Denmark
- <sup>17</sup>Hamburg Centre for Pediatric and Adolescent Rheumatology, Schön Klinik Hamburg Eilbek, Hamburg, Germany
- <sup>18</sup>Department of Dermatology, Dermatology & Skin Care Clinic, Buochs, Switzerland
- <sup>19</sup>Department of Dermatology and Venereology, University of Turku and Turku University Hospital, Turku, Finland
- <sup>20</sup>Department of Dermatology, Venereology and Dermatocology, Semmelweis University, Budapest, Hungary
- <sup>21</sup>The Skin Clinic, Department of Dermato-Allergology, Copenhagen University Hospital, Copenhagen, Denmark
- <sup>22</sup>Department of Dermatology, Medical University of Warsaw, Warsaw, Poland
- <sup>23</sup>Department of Dermatology and Allergology, University of Helsinki and Helsinki University Hospital, Helsinki, Finland
- <sup>24</sup>Department of Medical Sciences, Dermatologic Clinic, University of Turin, Turin, Italy
- <sup>25</sup>Department of Dermatology and Pediatric Dermatology, National Centre for Rare Skin Disorders, Hôpital Saint-Andre, University of Bordeaux, CNRS, Immuno CencEpT UMR 5164, Bordeaux, France
- <sup>26</sup>Department of Dermatology, Universitätsklinikum Erlangen, Erlangen, Germany
- <sup>27</sup>Department of Dermatology and Venereology, University Hospital Halle, Halle (Saale), Germany
- <sup>28</sup>Private Practice, Medical University of Vienna, Vienna, Austria
- <sup>29</sup>Department of Dermatology, Medical University of Graz, Graz, Austria

<sup>30</sup>Division of Allergy and Immunology, Department of Dermatology, Venereology and Allergology, University Hospital Charité—Universitätsmedizin Berlin, Berlin, Germany

<sup>31</sup>Department of Dermatology and Venereology, and Translational Matrix Biology, University of Cologne, Cologne, Germany

## ACKNOWLEDGEMENTS

The authors thank the patients, the investigators and their teams who took part in this study. The authors also acknowledge Antonio Cuzzio, Adina Frasin, Elisabeth Aberer, Camille Frances, Ulrike Just, Aurora Parodi, Antoine Pettit, Annamari Ranki, Júlia Maria Sánchez-Schmidt, Alain Taieb, Nora Wutte, Jean-David Bouaziz, Dorota Krasowska, Cate Orteu for their work on the initial version of these consensus statements, Ara Cho, MD, for her insights on this article, and Hannah Brechka, PhD from Costello Medical, United Kingdom, for editorial assistance based on the authors' input and direction. VS is Senior Clinical Investigator of the Research Foundation of Flanders (Belgium; 1.8.029.20 N).

## FUNDING INFORMATION

Editorial services was provided by Costello Medical, and funded by an independent medical writing grant provided by Mallinckrodt Pharmaceuticals. Mallinckrodt played no role in the development and review of the article, or approval to submit the article for publication. These tasks were solely the responsibility of the authors.

## CONFLICT OF INTEREST STATEMENT

Prof. Dr. Robert Knobler received consultancy fees from Therakos/Mallinckrodt and Actelion. Dr. M. Geroldinger-Simić, PhD, received fees for lectures from Janssen and for attending meetings from Astra Zeneca. Prof. Dr. Alexander Kreuter received fees for lectures and article preparation from Actelion and had advisory board membership with Sanofi Pasteur, Merck Sharp and Dohme and AbbVie. Prof. Dr. Nicolas Hunzelmann received lecture fees from Boehringer and Janssen. Dr. Pia Moinszadeh received lecture fees from Boehringer Ingelheim and received a research grant, consulting honoraria, fees for lectures and participation in review activities from Actelion. Prof. Dr. Franco Rongioletti received research grants from Abbvie and Almirall. Prof. Dr. Christopher Denton received research grants from Actelion, Roche and CSL Behring, and consulting fees from Actelion, Glaxo Smith Kline, Bayer and Roche. Prof. Dr. Thomas Krieg, Prof. Dr. L. Mouthon, Prof. Armando Gabrielli, M. Bagot, Ass. Prof. Dr. A.B Olesen, Prof. Veli-Matti Kähäri, S. Kárpáti, Prof. Malgorzata Olszewska, Assoc. Prof. Dr. Jaana Panelius, Pietro Quaglini, Prof. Dr. Julien Seneschal, M. Sticherling and A. Skrok report no conflicts of interest. Prof. M. Cutolo received research grants from Boehringer Ingelheim and Horizon. V. Smith has received grant/research support to her institution from the Research Foundation Flanders, Belgian Fund for Scientific Research in Rheumatic Diseases, Janssen-Cilag and Boehringer-Ingelheim; consulting fees from Boehringer-Ingelheim (payments made to self and institution) and Janssen-Cilag (payments made

to institution); support for attending meetings and/or travel from Boehringer Ingelheim (payments made to institution). I. Foeldvari has received research grants from Joachim Herz Stiftung and consultancy fees from Eli Lilly, Pfizer, MEDAC, AMGEM and Novartis. Dr. Ahmad Jalili received research grants, consultancy honoraria and fees for lectures and participation in review activities from AbbVie, Amgen, Bayer, BioMed, Boehringer-Ingelheim, Bristol-Myers Squibb, Eli Lilly, Galderma, GlaxoSmithKline, Janssen-Cilag, LEO Pharma, Merz Pharma, Novartis, Pfizer, Sanofi, Sandoz and UCB Pharma. Dr. K. Kofoed has received fees for lectures from Eli Lilly, Astra Zeneca, Abbvie, Bristol-Myers Squibb, LEO Pharma, Astra Zeneca, Orifarm and Boehringer Ingelheim and fees for consulting from Eli Lilly, Pfizer and Janssen. Prof. Dr. Cord Sunderkötter has received consulting fees from Boehringer Ingelheim, Biotest AG and Janssen Cilag; payment for lectures from Boehringer Ingelheim, Biotest AG and Janssen Cilag; and support for attending meetings from Boehringer Ingelheim and Pfizer. Prof. Dr. Adrian Tanew has received consulting honoraria or lecture fees from Amgen, Incyte, mibe GesmbH and Pelpharam. Prof. Dr. Peter Wolf has received research grants, speaker and/or consulting honoraria, and/or travel refunds from Actavis, Amgen GmbH, Almirall, Boehringer-Ingelheim, BMS, Celgene, Eli Lilly, Janssen, Leo Pharma, Novartis, Merck Sharp & Dohme, Therakos/Mallinckrodt, Roche, Sandoz, Sanofi, Pfizer and UCB. M. Worm has received of honoraria and/or consultation fees by the following companies: Novartis Pharma GmbH, Sanofi-Aventis Deutschland GmbH, DBV Technologies S.A, Aimmune Therapeutics UK Limited, Regeneron Pharmaceuticals, Inc, Leo Pharma GmbH, Boehringer Ingelheim Pharma GmbH & Co.KG, ALK-Abelló Arzneimittel GmbH, Lilly Deutschland GmbH, Kymab Limited, Amgen GmbH, Abbvie Deutschland GmbH & Co. KG, Pfizer Pharma GmbH, Mylan Germany GmbH (A Viatrix Company), AstraZeneca GmbH, Lilly Deutschland GmbH and GlaxoSmithKline GmbH & Co. KG. L. Rudnicka has had an advisory board membership with Pfizer, Sandoz, Sanofi, L'Oreal and has provided medical lectures for Leo Pharma, L'Oréal, UCB and Pierre-Fabre. ICMJE Disclosure of Interest form was used to collect conflicts of interest.

#### DATA AVAILABILITY STATEMENT

Data sharing is not applicable to this article as no new data were created or analyzed in this study.

#### ETHICS STATEMENT

The patients in this article have given written informed consent to publication of their case details.

#### ORCID

Robert Knobler  <https://orcid.org/0000-0002-7380-7062>  
 Pia Moynadeh  <https://orcid.org/0000-0002-8784-8615>  
 Franco Rongioletti  <https://orcid.org/0000-0002-2227-581X>  
 Christopher Denton  <https://orcid.org/0000-0003-3975-8938>  
 Martine Bagot  <https://orcid.org/0000-0002-1631-5192>  
 Ahmad Jalili  <https://orcid.org/0000-0002-8349-4530>

Pietro Quaglini  <https://orcid.org/0000-0003-4185-9586>  
 Julien Seneschal  <https://orcid.org/0000-0003-1139-0908>  
 Adrian Tanew  <https://orcid.org/0000-0002-4433-2790>  
 Lidia Rudnicka  <https://orcid.org/0000-0002-8308-1023>

#### REFERENCES

- Rongioletti F, Merlo G, Cinotti E, Fausti V, Cozzani E, Cribier B, et al. Scleromyxedema: a multicenter study of characteristics, comorbidities, course, and therapy in 30 patients. *J Am Acad Dermatol*. 2013;69(1):66–72.
- Rongioletti F, Rebora A. Mucinoses. In: Bologna J, Jorizzo JL, Schaffer JV, editors. *Dermatology*. Philadelphia: Elsevier; 2012. p. 687.
- Rongioletti F. Lichen myxedematosus (papular mucinosis): new concepts and perspectives for an old disease. *Semin Cutan Med Surg*. 2006;25(2):100–4.
- Cokonis Georgakis CD, Falasca G, Georgakis A, Heymann WR. Scleromyxedema. *Clin Dermatol*. 2006;24(6):493–7.
- Mahévas T, Arnulf B, Bouaziz JD, Livideanu CB, Osio A, Servy A, et al. Plasma cell-directed therapies in monoclonal gammopathy-associated scleromyxedema. *Blood*. 2020;135(14):1101–10.
- Mecoli CA, Talbot CC Jr, Fava A, Cheadle C, Boin F, Wigley FM, et al. Clinical and molecular phenotyping in scleromyxedema pretreatment and posttreatment with intravenous immunoglobulin. *Arthritis Care Res*. 2020;72(6):761–7.
- Kalli F, Cioni M, Parodi A, Altosole T, Ferrera F, Barra G, et al. Increased frequency of interleukin-4 and reduced frequency of interferon- $\gamma$  and IL-17-producing CD4+ and CD8+ cells in scleromyxedema. *J Eur Acad Dermatol Venereol*. 2020;34(5):1092–7.
- Harper RA, Rispler J. Lichen myxedematosus serum stimulates human skin fibroblast proliferation. *Science*. 1978;199(4328):545–7.
- Ferrarini M, Helfrich DJ, Walker ER, Medsger TA Jr, Whiteside TL. Scleromyxedema serum increases proliferation but not the glycosaminoglycan synthesis of dermal fibroblasts. *J Rheumatol*. 1989;16(6):837–41.
- Yaron M, Yaron I, Yust I, Brenner S. Lichen myxedematosus (scleromyxedema) serum stimulates hyaluronic acid and prostaglandin E production by human fibroblasts. *J Rheumatol*. 1985;12(1):171–5.
- Yeung CK, Loong F, Kwong YL. Scleromyxoedema due to a plasma cell neoplasm: rapid remission with bortezomib, thalidomide and dexamethasone. *Br J Haematol*. 2012;157(4):411.
- Migkou M, Gkatzamanidou M, Terpos E, Dimopoulos MA, Kastritis E. Response to bortezomib of a patient with scleromyxedema refractory to other therapies. *Leuk Res*. 2011;35(11):e209–e211.
- Rongioletti F, Cattarini G, Sottofattori E, Rebora A. Granulomatous reaction after intradermal injections of hyaluronic acid gel. *Arch Dermatol*. 2003;139(6):815–6.
- Rongioletti F, Hazini A, Rebora A. Coma associated with scleromyxoedema and interferon alfa therapy. Full recovery after steroids and cyclophosphamide combined with plasmapheresis. *Br J Dermatol*. 2001;144(6):1283–4.
- Fleming KE, Virmani D, Sutton E, Langley R, Corbin J, Pasternak S, et al. Scleromyxedema and the dermatoneuro syndrome: case report and review of the literature. *J Cutan Pathol*. 2012;39(5):508–17.
- Berger JR, Dobbs MR, Terhune MH, Maragos WF. The neurologic complications of scleromyxedema. *Medicine*. 2001;80(5):313–9.
- Rey JB, Luria RB. Treatment of scleromyxedema and the dermatoneuro syndrome with intravenous immunoglobulin. *J Am Acad Dermatol*. 2009;60(6):1037–41.
- Espinosa A, De Miguel E, Morales C, Fonseca E, Gijon-Banos J. Scleromyxedema associated with arthritis and myopathy: a case report. *Clin Exp Rheumatol*. 1993;11(5):545–7.
- Jamieson TW, De Smet AA, Stechschulte DJ. Erosive arthropathy associated with scleromyxedema. *Skeletal Radiol*. 1985;14(4):286–90.

20. Helfrich DJ, Walker ER, Martinez AJ, Medsger TA Jr. Scleromyxedema myopathy: case report and review of the literature. *Arthritis Rheum*. 1988;31(11):1437–41.
21. Launay D, Hatron PY, Delaporte E, Hachulla E, Devulder B, Piette F. Scleromyxedema (lichen myxedematosus) associated with dermatomyositis. *Br J Dermatol*. 2001;144(2):359–62.
22. Rothe MJ, Rivas R, Gould E, Kerdel FA. Scleromyxedema and severe myositis. *Int J Dermatol*. 1989;28(10):657–60.
23. Ozdag F, Akar A, Eroglu E, Erbil H. Acute rhabdomyolysis during the treatment of scleromyxedema with interferon alfa. *J Dermatolog Treat*. 2001;12(3):167–9.
24. Pomann JJ, Rudner EJ. Scleromyxedema revisited. *Int J Dermatol*. 2003;42(1):31–5.
25. De Simone C, Castriota M, Carbone A, Bettolo PM, Pieroni M, Rongioletti F. Cardiomyopathy in scleromyxedema: report of a fatal case. *Eur J Dermatol*. 2010;20(6):852–3.
26. Morris-Jones R, Staughton RC, Walker M, Sheridan DJ, Rajappan K, Leonard J, et al. Lichen myxoedematosus with associated cardiac abnormalities. *Br J Dermatol*. 2001;144(3):594–6.
27. Dinneen AM, Dicken CH. Scleromyxedema. *J Am Acad Dermatol*. 1995;33(1):37–43.
28. Blum M, Wigley FM, Hummers LK. Scleromyxedema: a case series highlighting long-term outcomes of treatment with intravenous immunoglobulin (IVIG). *Medicine*. 2008;87(1):10–20.
29. Le Moigne M, Mazereeuw-Hautier J, Bonnetblanc JM, Astudillo L, D'Incan M, Bessis D, et al. Clinical characteristics, outcome of scleromyxoedema: a retrospective multicentre study. *Ann Dermatol Venereol*. 2010;137(12):782–8.
30. Rapp MF, Guram M, Konrad HR, Mody N, Trapp R. Laryngeal involvement in scleromyxedema: a case report. *Otolaryngol Head Neck Surg*. 1991;104(3):362–5.
31. Lee YH, Sahu J, O'Brien MS, D'Agati VD, Jimenez SA. Scleroderma renal crisis-like acute renal failure associated with mucopolysaccharide accumulation in renal vessels in a patient with scleromyxoedema. *J Clin Rheumatol*. 2011;17(6):318–22.
32. Godby A, Bergstresser PR, Chaker B, Pandya AG. Fatal scleromyxoedema: report of a case and review of the literature. *J Am Acad Dermatol*. 1998;38(2 Pt 2):289–94.
33. Loggini B, Pingitore R, Avvenente A, Giuliano G, Barachini P. Lichen myxedematosus with systemic involvement: clinical and autopsy findings. *J Am Acad Dermatol*. 2001;45(4):606–8.
34. Gonzalez J, Palangio M, Schwartz J, Klainer AS, Bisaccia E. Scleromyxedema with dermato-neuro syndrome. *J Am Acad Dermatol*. 2000;42(5 Pt 2):927–8.
35. Chan JC, Trendell-Smith NJ, Yeung CK. Scleromyxedema: a cutaneous paraneoplastic syndrome associated with thymic carcinoma. *J Clin Oncol*. 2012;30(3):e27–e29.
36. Alfadley A, Al Hoqaifi I, Al Eisa A. Scleromyxedema: possible association with seminoma. *J Am Acad Dermatol*. 2000;42(5 Pt 2):875–8.
37. Oh SJ, Oh SH, Jun JY, Park JH, Lee JH, Lee DY, et al. Paraneoplastic atypical scleromyxedema with advanced gastric cancer. *JAAD Case Rep*. 2017;3(5):376–8.
38. Hardie RA, Hunter JA, Urbaniak S, Habeshaw JA. Spontaneous resolution of lichen myxoedematosus. *Br J Dermatol*. 1979;100(6):727–30.
39. Rongioletti F, Rebora A. Cutaneous mucinoses: microscopic criteria for diagnosis. *Am J Dermatopathol*. 2001;23(3):257–67.
40. Rongioletti F, Rebora A. Updated classification of papular mucinosis, lichen myxedematosus, and scleromyxedema. *J Am Acad Dermatol*. 2001;44(2):273–81.
41. Stücker M, Nowack U, Röchling A, Bacharach-Buhles M, el Gammal S, Panz B, et al. Sweat gland proliferations in scleromyxedema. *Am J Dermatopathol*. 1999;21(3):259–64.
42. Gonzalez Santiago TM, Lehman JS, Buonaccorsi JN, Kalaaji AN, Wieland CN. Frequency of cutis laxa-like clinical features and elastolysis in scleromyxedema: a retrospective clinicopathologic study of 19 patients with scleromyxedema. *J Cutan Pathol*. 2016;43(3):246–51.
43. Rongioletti F, Cozzani E, Parodi A. Scleromyxedema with an interstitial granulomatous-like pattern: a rare histologic variant mimicking granuloma annulare. *J Cutan Pathol*. 2010;37(10):1084–7.
44. Rongioletti F, Merlo G, Carli C, Cribrier B, Metzke D, Calonje E, et al. Histopathologic characteristics of scleromyxedema: a study of a series of 34 cases. *J Am Acad Dermatol*. 2016;74(6):1194–200.
45. Delyon J, Bézier M, Rybojad M, Brière J, Validire P, Bagot M, et al. Specific lymph node involvement in scleromyxedema: a new diagnostic entity for hypermetabolic lymphadenopathy. *Virchows Arch*. 2013;462(6):679–83.
46. Farmer ER, Hambrick GW Jr, Shulman LE. Papular mucinosis: a clinicopathologic study of four patients. *Arch Dermatol*. 1982;118(1):9–13.
47. Krajnc I, Vizjak A, Hvala A, Jurcic V, Rozman B. Significance of histopathologic analysis of skin lesions in scleromyxedema. Light microscopy, electron microscopy, immunohistochemistry and immunofluorescence microscopy. *Acta Med Austriaca*. 1998;25(3):109–12.
48. Mendes Bastos P, Borges AS, Cardoso JC, Oliveira A. Dermoscopy and reflectance confocal microscopy for the diagnosis of scleromyxoedema. *JAAD Case Rep*. 2019;5(5):451–3.
49. Serra S, Ambrósio C, João Salvador M, Serra D, Reis P, Malcata A. A cutaneous thickening case. *Acta Reumatol Port*. 2010;35(1):66–71.
50. Ferreli C, Gasparini G, Parodi A, Cozzani E, Rongioletti F, Atzori L. Cutaneous manifestations of scleroderma and scleroderma-like disorders: a comprehensive review. *Clin Rev Allergy Immunol*. 2017;53(3):306–36.
51. Weedon D. Cutaneous mucinosis. In: Hurtt MA, Weedon D, editors. *Weedon's skin pathology*. 3rd ed. London: Elsevier; 2010. p. 353.
52. Guarneri A, Cioni M, Rongioletti F. High-dose intravenous immunoglobulin therapy for scleromyxoedema: a prospective open-label clinical trial using an objective score of clinical evaluation system. *J Eur Acad Dermatol Venereol*. 2017;31(7):1157–60.
53. Knobler R, Moizadeh P, Hunzelmann N, Kreuter A, Cozzio A, Mouthon L, et al. European dermatology forum S1-guideline on the diagnosis and treatment of sclerosing diseases of the skin, part 2: scleromyxedema, scleredema and nephrogenic systemic fibrosis. *J Eur Acad Dermatol Venereol*. 2017;31(10):1581–94.
54. Samuelsson A, Towers TL, Ravetch JV. Anti-inflammatory activity of IVIG mediated through the inhibitory Fc receptor. *Science*. 2001;291(5503):484–6.
55. Molina V, Blank M, Shoenfeld Y. Intravenous immunoglobulin and fibrosis. *Clin Rev Allergy Immunol*. 2005;29(3):321–6.
56. Körber A, Franckson T, Grabbe S, Dissemmond J. Successful therapy of scleromyxoedema Arndt-Gottron with low-dose intravenous immunoglobulin. *J Eur Acad Dermatol Venereol*. 2007;21(4):553–4.
57. Bidier M, Zschoche C, Gholam P, Enk AH, Hadaschik EN. Scleromyxoedema: clinical follow-up after successful treatment with high-dose immunoglobulins reveals different long-term outcomes. *Acta Derm Venereol*. 2012;92(4):408–9.
58. Righi A, Schiavon F, Jablonska S, Doria A, Blaszczak M, Rondinone R, et al. Intravenous immunoglobulins control scleromyxoedema. *Ann Rheum Dis*. 2002;61(1):59–61.
59. Binitha MP, Nandakumar G, Thomas D. Suspected cardiac toxicity to intravenous immunoglobulin used for treatment of scleromyxoedema. *Indian J Dermatol Venereol Leprol*. 2008;74(3):248–50.
60. Sroa N, Campbell S, Bechtel M. Intravenous immunoglobulin therapy for scleromyxedema: a case report and review of literature. *J Drugs Dermatol*. 2010;9(3):263–5.
61. Gholam P, Hartmann M, Enk A. Arndt-Gottron scleromyxoedema: successful therapy with intravenous immunoglobulins. *Br J Dermatol*. 2007;157(5):1058–60.
62. Wright RC, Franco RS, Denton D, Blaney DJ. Scleromyxedema. *Arch Dermatol*. 1976;112(1):63–6.
63. Rayson D, Lust JA, Duncan A, Su WP. Scleromyxedema: a complete response to prednisone. *Mayo Clin Proc*. 1999;74(5):481–4.
64. Lin YC, Wang HC, Shen JL. Scleromyxedema: an experience using treatment with systemic corticosteroid and review of the published work. *J Dermatol*. 2006;33(3):207–10.

65. Kreuter A, Altmeyer P. High-dose dexamethasone in scleromyxedema: report of 2 additional cases. *J Am Acad Dermatol*. 2005;53(4):739–40.
66. Horn KB, Horn MA, Swan J, Singhal S, Guitart J. A complete and durable clinical response to high-dose dexamethasone in a patient with scleromyxedema. *J Am Acad Dermatol*. 2004;51(2 Suppl):S120–S123.
67. Kreuter A, Gambichler T, Breuckmann F, Rotterdam S, Freitag M, Stuecker M, et al. Pulsed high-dose corticosteroids combined with low-dose methotrexate in severe localized scleroderma. *Arch Dermatol*. 2005;141(7):847–52.
68. Efthimiou P, Blanco M. Intravenous gammaglobulin and thalidomide may be an effective therapeutic combination in refractory scleromyxedema: case report and discussion of the literature. *Semin Arthritis Rheum*. 2008;38(3):188–94.
69. Sansbury JC, Cocuroccia B, Jorizzo JL, Gubinelli E, Gisondi P, Girolomoni G. Treatment of recalcitrant scleromyxedema with thalidomide in 3 patients. *J Am Acad Dermatol*. 2004;51(1):126–31.
70. Guarenti I, Sebastiani V, Pinto G, de Souza PR, de Almeida JH. Successful treatment of scleromyxedema with oral thalidomide. *Int J Dermatol*. 2013;52(5):631–2.
71. Amini-Adle M, Thieulent N, Dalle S, Balme B, Thomas L. Scleromyxedema: successful treatment with thalidomide in two patients. *Dermatology*. 2007;214(1):58–60.
72. Jacob SE, Fien S, Kerdel FA. Scleromyxedema, a positive effect with thalidomide. *Dermatology*. 2006;213(2):150–2.
73. Martins A, Paiva LMJ, Tavares Belo R, Rodrigues JC. Scleromyxedema—thalidomide therapy. *J Eur Acad Dermatol Venereol*. 2008;22(5):622–4.
74. Thyssen JP, Zachariae C, Menné T. Successful treatment of scleromyxedema using thalidomide. *J Eur Acad Dermatol Venereol*. 2006;20(10):1396–7.
75. Brunet-Possenti F, Hermine O, Marinho E, Crickx B, Descamps V. Combination of intravenous immunoglobulins and lenalidomide in the treatment of scleromyxedema. *J Am Acad Dermatol*. 2013;69(2):319–20.
76. Cañueto J, Labrador J, Román C, Santos-Briz Á, Contreras T, Gutiérrez NC, et al. The combination of bortezomib and dexamethasone is an efficient therapy for relapsed/refractory scleromyxedema: a rare disease with new clinical insights. *Eur J Haematol*. 2012;88(5):450–4.
77. Feasel AM, Donato ML, Duvic M. Complete remission of scleromyxedema following autologous stem cell transplantation. *Arch Dermatol*. 2001;137(8):1071–2.
78. Bos R, de Waal EG, Kuiper H, Hazenberg BP, Vellenga E. Thalidomide and dexamethasone followed by autologous stem cell transplantation for scleromyxoedema. *Rheumatology*. 2011;50(10):1925–6.
79. Shayegi N, Alakel N, Middeke JM, Schetelig J, Mantovani-Löffler L, Bornhäuser M. Allogeneic stem cell transplantation for the treatment of refractory scleromyxedema. *Transl Res*. 2015;165(2):321–4.
80. River Y, Levy I, Gilead L, Orbach H, Almog Y. Fever, convulsions and coma in scleromyxedema: a “Dermato-Neuro Syndrome”. *Neurology*. 1996;46(6):1778–9.
81. Fett NM, Toporcer MB, Dalmau J, Shinohara MM, Vogl DT. Scleromyxedema and dermatoneuro syndrome in a patient with multiple myeloma effectively treated with dexamethasone and bortezomib. *Am J Hematol*. 2011;86(10):893–6.
82. Bonnetblanc JM, Bedane C. Regression of scleromyxedema with topical betamethasone and dimethyl sulfoxide: a 30-month follow-up. *Arch Dermatol*. 1991;127(11):1733–4.
83. Reynolds NJ, Collins CM, Burton JL. Discrete papular mucinosis responding to intralesional and topical steroids. *Arch Dermatol*. 1992;128(6):857–8.
84. Hisler BM, Savoy LB, Hashimoto K. Improvement of scleromyxedema associated with isotretinoin therapy. *J Am Acad Dermatol*. 1991;24(5 Pt 2):854–7.
85. Milam CP, Cohen LE, Fenske NA, Ling NS. Scleromyxedema: therapeutic response to isotretinoin in three patients. *J Am Acad Dermatol*. 1988;19(3):469–77.
86. Tschén JA, Chang JR. Scleromyxedema: treatment with interferon alfa. *J Am Acad Dermatol*. 1999;40(2 Pt 2):303–7.
87. Saigo H, Tashiro A, Fujita S, Matsui M, Shibata S, Takeshita H, et al. Successful treatment of intractable scleromyxedema with cyclosporin A. *Dermatology*. 2003;207(4):410–1.
88. Kuldeep CM, Mittal AK, Gupta LK, Paliwal VK, Sharma P, Garg A. Successful treatment of scleromyxedema with dexamethasone cyclophosphamide pulse therapy. *Indian J Dermatol Venereol Leprol*. 2005;71(1):44–5.
89. Mehta V, Balachandran C, Rao R. Arndt Gottron scleromyxedema: successful response to treatment with steroid minipulse and methotrexate. *Indian J Dermatol*. 2009;54(2):193–5.
90. Schirren CG, Betke M, Eckert F, Przybilla B. Arndt-Gottron scleromyxedema. Case report and review of therapeutic possibilities. *Hautarzt*. 1992;43(3):152–7.
91. Davis LS, Sanal S, Sangueza OP. Treatment of scleromyxedema with 2-chlorodeoxyadenosine. *J Am Acad Dermatol*. 1996;35(2 Pt 2):288–90.
92. Rongioletti F, Rebora A. Worsening of lichen myxedematosus during interferon alfa-2a therapy for chronic active hepatitis C. *J Am Acad Dermatol*. 1998;38(5 Pt 1):760–1.
93. Brenner M, Herzinger T, Berking C, Plewig G, Degitz K. Phototherapy and photochemotherapy of sclerosing skin diseases. *Photodermatol Photoimmunol Photomed*. 2005;21(3):157–65.
94. Kantor GR, Bergfeld WF, Katzin WE, Reynolds OD, Biscardi AP, Lobur DM, et al. Scleromyxedema associated with scleroderma renal disease and acute psychosis. *J Am Acad Dermatol*. 1986;14(5 Pt 2):879–88.
95. Rampino M, Garibaldi E, Ragona R, Ricardi U. Scleromyxedema: treatment of widespread cutaneous involvement by total skin electron-beam therapy. *Int J Dermatol*. 2007;46(8):864–7.
96. Vieyra-García PA, Wolf P. A deep dive into UV-based phototherapy: mechanisms of action and emerging molecular targets in inflammation and cancer. *Pharmacol Ther*. 2021;222:107784.
97. Yamazaki S, Fujisawa T, Yanatori A, Yamakage A. A case of lichen myxedematosus with clearly exacerbated skin eruptions after UVB irradiation. *J Dermatol*. 1995;22(8):590–3.
98. Arginelli F, Paganelli A, Rongioletti F, Pellacani G, Conti A. Ineffectiveness of infliximab CT-P13 for the treatment of scleromyxedema: a case report. *Dermatol Ther*. 2018;31(2):e12583.
99. Acikel C, Karagoz H, Kucukodaci Z. Surgical treatment of facial disfigurement due to lichen myxedematosus. *Dermatol Surg*. 2009;35(5):875–7.
100. Kaymen AH, Nasr A, Grekin RC. The use of carbon dioxide laser in lichen myxedematosus. *J Dermatol Surg Oncol*. 1989;15(8):862–5.
101. Greenberg LM, Geppert C, Worthen HG, Good RA. Scleredema “Adultorum” in children. Report of three cases with histochemical study and review of world literature. *Pediatrics*. 1963;32:1044–54.
102. Cole GW, Headley J, Skowsky R. Scleredema diabeticorum: a common and distinct cutaneous manifestation of diabetes mellitus. *Diabetes Care*. 1983;6(2):189–92.
103. Sattar MA, Diab S, Sugathan TN, Sivanandasingham P, Fenech FF. Scleroderma diabeticorum: a minor but often unrecognized complication of diabetes mellitus. *Diabet Med*. 1988;5(5):465–8.
104. Morais P, Almeida M, Santos P, Azevedo F. Scleredema of Buschke following *Mycoplasma pneumoniae* respiratory infection. *Int J Dermatol*. 2011;50(4):454–7.
105. Venencie PY, Powell FC, Su WP, Perry HO. Scleredema: a review of thirty-three cases. *J Am Acad Dermatol*. 1984;11(1):128–34.
106. Sanchez-Díaz M, Lobato-Cano R, Salvador-Rodríguez L, Lopez-Delgado D, Espadafor-Lopez B, Vilchez-Marquez F, et al. Scleredema developing after SARS-CoV-2 infection: a possible novel skin manifestation of coronavirus disease. *Eur J Dermatol*. 2022;32(1):124–45.
107. Angeli-Besson C, Koeppel MC, Jacquet P, Andrac L, Sayag J. Electron-beam therapy in scleredema adultorum with associated monoclonal hypergammaglobulinaemia. *Br J Dermatol*. 1994;130(3):394–7.

108. Chang HK, Kim YC, Kwon BS. Widespread scleredema accompanied with a monoclonal gammopathy in a patient with advanced ankylosing spondylitis. *J Korean Med Sci.* 2004;19(3):481–3.
109. McFadden N, Ree K, Soyland E, Larsen TE. Scleredema adutorum associated with a monoclonal gammopathy and generalized hyperpigmentation. *Arch Dermatol.* 1987;123(5):629–32.
110. Szturz P, Adam Z, Vašků V, Feit J, Krejčí M, Pour L, et al. Complete remission of multiple myeloma associated scleredema after bortezomib-based treatment. *Leuk Lymphoma.* 2013;54(6):1324–6.
111. Grudeva-Popova J, Dobrev H. Biomechanical measurement of skin distensibility in scleredema of Buschke associated with multiple myeloma. *Clin Exp Dermatol.* 2000;25(3):247–9.
112. Salisbury JA, Shallcross H, Leigh IM. Scleredema of Buschke associated with multiple myeloma. *Clin Exp Dermatol.* 1988;13(4):269–70.
113. Dziadzio M, Anastasiades CP, Hawkins PN, Potter M, Gabrielli A, Brough GM, et al. From scleredema to AL amyloidosis: disease progression or coincidence? Review of the literature. *Clin Rheumatol.* 2006;25(1):3–15.
114. Krakowski A, Covo J, Berlin C. Diabetic scleredema. *Harefuah.* 1973;84(9):498–500.
115. Hines A, Alavi A, Davis MDP. Cutaneous manifestations of diabetes. *Med Clin North Am.* 2021;105(4):681–97.
116. Hartley K, Huang C, Sykes A, Lamont D, Wlodek C. Scleredema in the setting of rheumatoid arthritis. *Australas J Dermatol.* 2020;61(1):e110–e111.
117. Ranganathan P. Infliximab-induced scleredema in a patient with rheumatoid arthritis. *J Clin Rheumatol.* 2005;11(6):319–22.
118. Miyagawa S, Dohi K, Tsuruta S, Shirai T. Scleredema of Buschke associated with rheumatoid arthritis and Sjögren's syndrome. *Br J Dermatol.* 1989;121(4):517–20.
119. Marill FG, Grould P. Scléroedème, première manifestation d'une dermatomyosite. *Bull Soc Fr Dermatol Syphiligr.* 1968;75(5):561–4.
120. Jacob N, Gleichmann U, Stadler R. Scleroedema adutorum bei sekundärem hyperparathyreoidismus. *Hautarzt.* 2002;53(2):121–5.
121. Berk MA, Lorincz AL. Scleredema adutorum of Buschke and primary hyperparathyroidism. *Int J Dermatol.* 1988;27(9):647–9.
122. Muralidharan S, Arun K, Ruckmani V, Devi B. Scleredema adutorum of Buschke associated with hypothyroidism and liver cirrhosis. *J Postgrad Med.* 2021;67(3):174–6.
123. Goss F, Krawietz W, Luderschmidt C, Pape GR. Scleroedema adutorum Buschke und primär biliäre Zirrhose bei einer 58jährigen Patientin. *Internist.* 1984;25(2):130–4.
124. Theodoridis A, Capetanakis J. Scleredema of Buschke with IgA deficiency. *Acta Derm Venereol.* 1979;59(2):182–3.
125. Rongioletti F, Ghigliotti G, Marchi R, de Reborja A. Cutaneous mucinoses and HIV infection. *Br J Dermatol.* 1998;139(6):1077–80.
126. Jacob JS, Cohen PR. Concurrent scleredema and pyoderma gangrenosum: case report and review of comorbid conditions. *Cureus.* 2020;12(12):e12188.
127. Matsunaga J, Hara M, Tagami H. Scleredema of Buschke associated with malignant insulinoma. *Br J Dermatol.* 1992;126(5):527–8.
128. Manchanda Y, Das S, Sharma VK, Srivastava DN. Scleredema associated with carcinoma of the gall bladder. *Br J Dermatol.* 2005;152(6):1373–4.
129. Yu JI, Park W, Lee KK. Scleredema adutorum of Buschke associated with a carcinoid tumor. *Int J Dermatol.* 2009;48(7):784–6.
130. Oyama N, Togashi A, Kaneko F, Yamamoto T. Two cases of scleredema with pituitary-adrenocortical neoplasms: an underrecognized skin complication. *J Dermatol.* 2012;39(2):193–5.
131. Dev N, Kumar R, Sharma S, Mahto K, Kumawat A. Scleroedema of Buschke in conjunction with ovarian carcinoma: rare association of a rare disease. *J R Coll Physicians Edinb.* 2020;50(1):32–4.
132. Tani N, Sugita K, Yamamoto O. Paclitaxel-related scleredema-like skin changes in a patient with breast cancer. *Australas J Dermatol.* 2018;59(3):e215–e217.
133. Beers WH, Ince A, Moore TL. Scleredema adutorum of Buschke: a case report and review of the literature. *Semin Arthritis Rheum.* 2006;35(6):355–9.
134. Schmidt KT, Gattuso P, Messmore H, Shrit MA, Massa M, Welykyj S. Scleredema and smoldering myeloma. *J Am Acad Dermatol.* 1992;26(2 Pt 2):319–21.
135. Meguerditchian C, Jacquet P, Béliard S, Benderitter T, Valéro R, Carsuzza F, et al. Scleredema adutorum of Buschke: an under recognized skin complication of diabetes. *Diabetes Metab.* 2006;32(5 Pt 1):481–4.
136. Varga J, Gotta S, Li L, Sollberg S, Di Leonardo M. Scleredema adutorum: case report and demonstration of abnormal expression of extracellular matrix genes in skin fibroblasts in vivo and in vitro. *Br J Dermatol.* 1995;132(6):992–9.
137. Farrell AM, Branfoot AC, Moss J, Papadaki L, Woodrow DF, Bunker CB. Scleredema diabeticorum of Buschke confined to the thighs. *Br J Dermatol.* 1996;134(6):1113–5.
138. Boin F, Hummers LK. Scleroderma-like fibrosing disorders. *Rheum Dis Clin North Am.* 2008;34(1):199–220.
139. Khanna D, Furst DE, Clements PJ, Allanore Y, Baron M, Czirkjak L, et al. Standardization of the modified Rodnan skin score for use in clinical trials of systemic sclerosis. *J Scleroderma Relat Disord.* 2017;2(1):11–8.
140. Fania L, Colonna L, Pagnanelli G, Abeni D, Annessi G, Mazzanti C. Scleredema of Buschke with prominent periorbital edema. *Int J Dermatol.* 2017;56(10):e193–e194.
141. Muhaidat J, Al-Qarqaz F, Alshiyab D. Unilateral linear induration of the skin: a case report of an unusual presentation of scleredema. *J Clin Aesthet Dermatol.* 2020;13(12):e53–e55.
142. Nakatsuji M, Ishimaru N, Ohnishi J, Mizuki S, Kanzawa Y, Kawano KNT, et al. Scleredema with biopsy-confirmed cardiomyopathy: a case report. *J Scleroderma Relat Disord.* 2021;6(3):311–5.
143. Vereecken P, Lutz R, Dobbeleer G, de Heenen M. Nonpitting induration of the back: scleredema adutorum of Buschke type III. *Arch Dermatol.* 1997;133(5):649, 52.
144. Martín C, Requena L, Manrique K, Manzarbeitia FD, Rovira A. Scleredema diabeticorum in a patient with type 2 diabetes mellitus. *Case Rep Endocrinol.* 2011;2011:31–4.
145. Giavedoni P, Pousa-Martínez M, Estany-Destal A, Ginarte M, Vázquez-Veiga HTL, Mascaró JM. Usefulness of high-frequency Doppler ultrasound skin thickness measurement for disease staging and assessing treatment response in patients with scleredema: a case-control study. *J Am Acad Dermatol.* 2022;86(1):189–91.
146. Cole GW, Handler SJ, Burnett K. The ultrasonic evaluation of skin thickness in scleredema. *J Clin Ultrasound.* 1981;9(9):501–3.
147. Foti R, Pasquale R, de Dal BY, Visalli E, Amato G, Gangemi P, et al. Clinical and histopathological features of scleroderma-like disorders: an update. *Medicina.* 2021;57:1275.
148. Raef HS, Nassim JS, Fedeles F. Indurated plaques on the back: distinguishing stiff skin syndrome from scleredema and morphea. *Int J Dermatol.* 2021;61(10):e393–e394.
149. Mitchell DC, Agnihothri R, Scott GA, Korman B, Richardson CT. A case of concurrent systemic sclerosis and scleredema. *JAAD Case Rep.* 2019;5(11):940–2.
150. Venturi M, Damevska K, Ferreli C, Pinna AL, Atzori L, Gocce G, et al. Scleredema of Buschke associated with lichen sclerosis: three cases. *Indian J Dermatol Venereol Leprol.* 2020;86(3):272–7.
151. Kroft EB, Berkhof NJ, van de Kerkhof PC, Gerritsen RM, de Jong EM. Ultraviolet A phototherapy for sclerotic skin diseases: a systematic review. *J Am Acad Dermatol.* 2008;59(6):1017–30.
152. Kokpol C, Rajatanavin N, Rattanakemakorn P. Successful treatment of scleredema diabeticorum by combining local PUVA and colchicine: a case report. *Case Rep Dermatol.* 2012;4(3):265–8.
153. Nakajima K, Iwagaki M, Ikeda M, Kodama H. Two cases of diabetic scleredema that responded to PUVA therapy. *J Dermatol.* 2006;33(11):820–2.
154. Grundmann-Kollmann M, Ochsendorf F, Zollner TM, Spieth K, Kaufmann R, Podda M. Cream PUVA therapy for scleredema adutorum. *Br J Dermatol.* 2000;142(5):1058–9.
155. Hager CM, Sobhi HA, Hunzelmann N, Wickenhauser C, Scharenberg R, Krieg T, et al. Bath-PUVA therapy in three patients

- with scleredema adultorum. *J Am Acad Dermatol*. 1998;38(2 Pt 1):240–2.
156. Yoshimura J, Asano Y, Takahashi T, Uwajima Y, Kagami S, Honda H, et al. A case of scleredema adultorum successfully treated with narrow-band ultraviolet B phototherapy. *Mod Rheumatol*. 2016;26(2):302–6.
  157. Sansom JE, Sheehan AL, Kennedy CT, Delaney TJ. A fatal case of scleredema of Buschke. *Br J Dermatol*. 1994;130(5):669–70.
  158. Mylona E, Goulinopoulou S, Skarnea A, Katsikas G, Skrepetou K, Nakos G, et al. Post-radiation scleredema adultorum and diffuse eosinophilic fasciitis in the same patient. *Scand J Rheumatol*. 2011;40:240–1.
  159. Mickel M, Jalili A, Gesslbauer C, Crevenna R. Implementation and evaluation of a rehabilitation concept in a patient suffering from Scleredema Adultorum Buschke: a case report. *Disabil Rehabil*. 2018;40:2833–5.
  160. Rongioletti F, Kaiser F, Cinotti E, Metz D, Battistella M, Calzavara-Pinton PG, et al. Scleredema: a multicentre study of characteristics, comorbidities, course and therapy in 44 patients. *J Eur Acad Dermatol Venereol*. 2015;29:2399–404.
  161. Breuckmann F, Appelhans C, Harati A, Rotterdam S, Altmeyer P, Kreuter A. Failure of low-dose methotrexate in the treatment of scleredema diabeticorum in seven cases. *Dermatology*. 2005;211:299–301.
  162. Mattheou-Vakali G, Ioannides D, Thomas T, Lazaridou E, Tsogas P, Minas A. Cyclosporine in scleredema. *J Am Acad Dermatol*. 1996;35:990–1.
  163. Ikeda Y, Suehiro T, Abe T, Yoshida T, Shinoki T, Tahara K, et al. Severe diabetic scleredema with extension to the extremities and effective treatment using prostaglandin E1. *Intern Med*. 1998;37:861–4.
  164. Hong KR, Hong JY, Chung EH, Lee SH, Lee SW, Kim JE. Monoclonal gammopathy-associated scleredema adultorum of Buschke in a patient with diabetes mellitus successfully treated with intravenous immunoglobulin and narrow-band ultraviolet B phototherapy: a case report. *Ann Dermatol*. 2021;33:586–8.
  165. Eastham AB, Femia AN, Velez NF, Smith HP, Vleugels RA. Paraproteinemia-associated scleredema treated successfully with intravenous immunoglobulin. *JAMA Dermatol*. 2014;150:788–9.
  166. Krasagakis K, Hettmannsperger U, Trautmann C, Thbbe B, Garbe C. Persistent scleredema of Buschke in a diabetic: improvement with high-dose penicillin. *Br J Dermatol*. 1996;134:597–8.
  167. Venturi C, Zendri E, Santini M, Grignaffini E, Ricci R, De Panfilis G. Scleredema of Buschke: remission with factor XIII treatment. *Int J Tissue React*. 2004;26:25–8.
  168. Sun M, Yang F, Hou M. Successful treatment of scleredema diabeticorum with tranilast: three case reports. *Diabetes Care*. 2018;41:e40–e41.
  169. Barnes M, Kumar V, Le TH, Nabeel S, Singh J, Rana V, et al. A case of paraproteinemia-associated scleredema successfully treated with thalidomide. *JAAD Case Rep*. 2020;6:1039–41.
  170. Bowen AR, Smith L, Zone JJ. Scleredema adultorum of Buschke treated with radiation. *Arch Dermatol*. 2003;139:780–4.
  171. Kim DH, Kim JH, Oh YW, Seo BH, Suh HS, Choi YS. Scleredema adultorum of Buschke treated by extracorporeal shock wave therapy. *J Eur Acad Dermatol Venereol*. 2020;34:e133–e135.
  172. Angeli-Besson C, Koeppel MC, Jacquet P, Andrac L, Sayag J. Electron-beam therapy in scleredema adultorum with associated monoclonal hypergammaglobulinaemia. *Br J Dermatol*. 1994;130:394–7.
  173. Stables GI, Taylor PC, Highet AS. Scleredema associated with paraproteinaemia treated by extracorporeal photopheresis. *Br J Dermatol*. 2000;142:781–3.

**How to cite this article:** Knobler R, Geroldinger-Simić M, Kreuter A, Hunzelmann N, Moinzadeh P, Rongioletti F, et al. Consensus statement on the diagnosis and treatment of sclerosing diseases of the skin, Part 2: Scleromyxoedema and scleroedema. *J Eur Acad Dermatol Venereol*. 2024;00:1–19. <https://doi.org/10.1111/jdv.19937>